

Rational for indications in
unicompartmental OA
Osteotomy *vs* UKA

M Bonnin MD, PhD

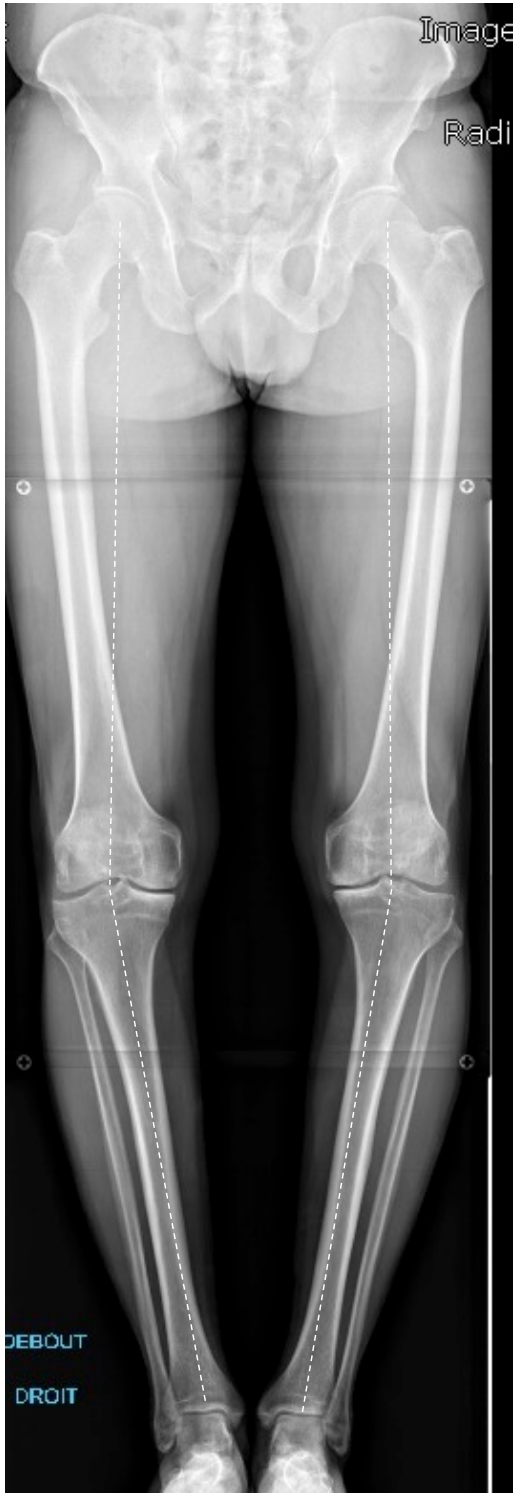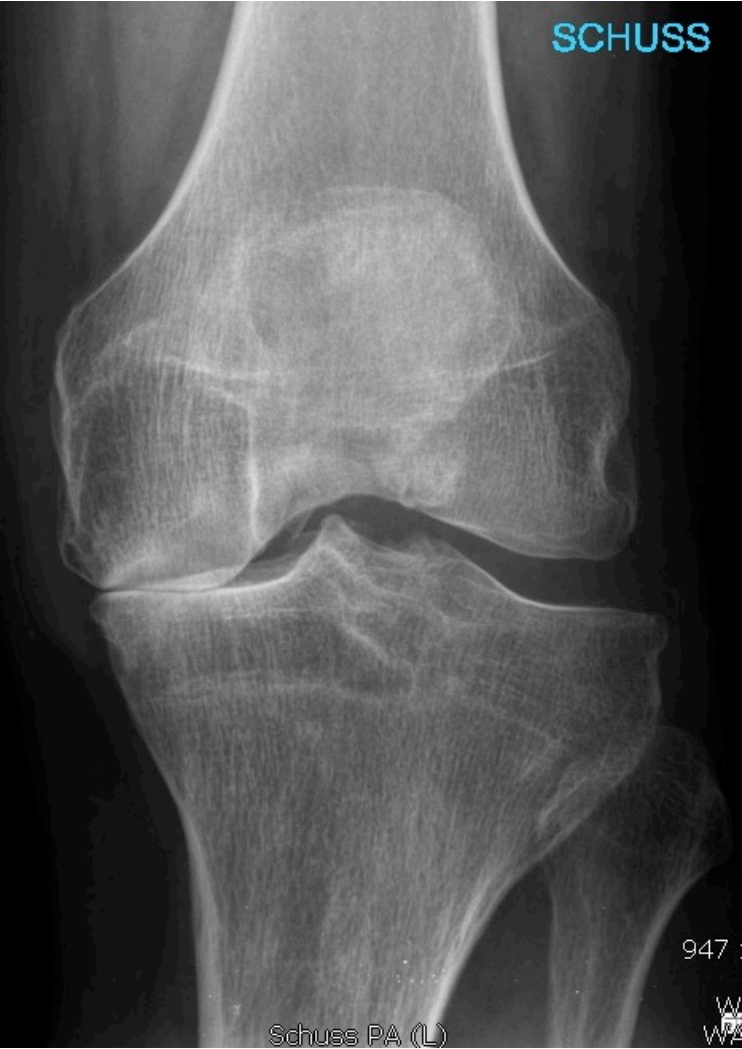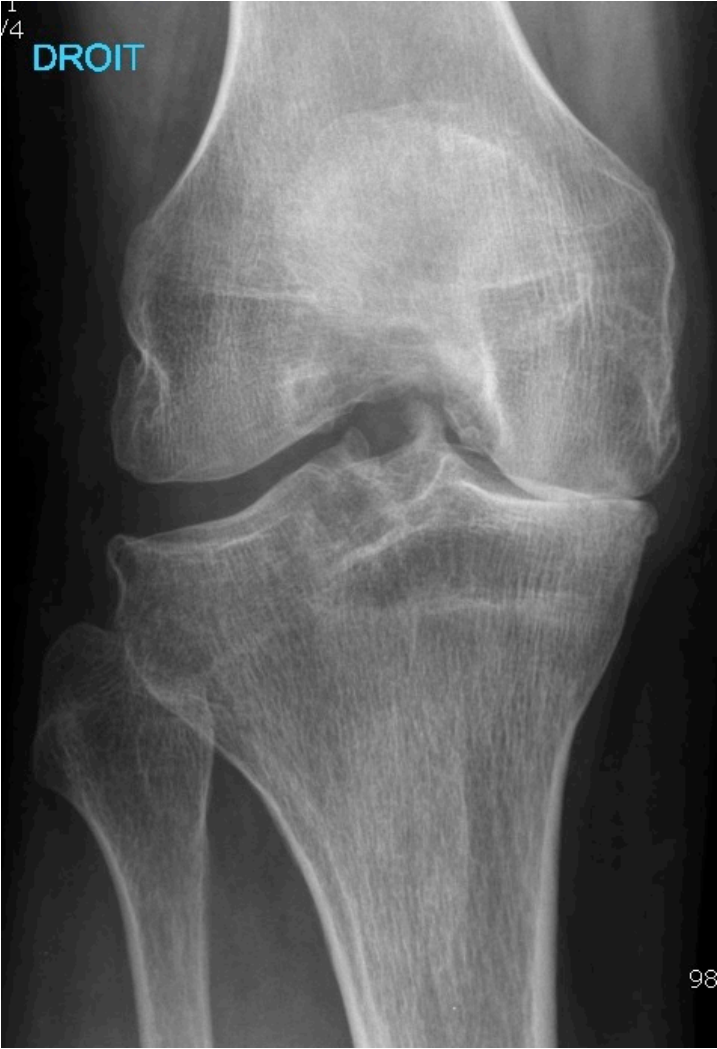Centre Orthopédique Santy Lyon France

		Osteotomy	UKA
1- Alignment	• Well-aligned		✓
	• Constitutional	✓	
	• Reductibility		✓
2- Patello-Femoral Joint			✓
3- Contro-lateral compartment		✓	✓
4- ACL			✓
5- Bone Quality		✓	✓
6- Age < 65		✓	
7- Spine correct		✓	

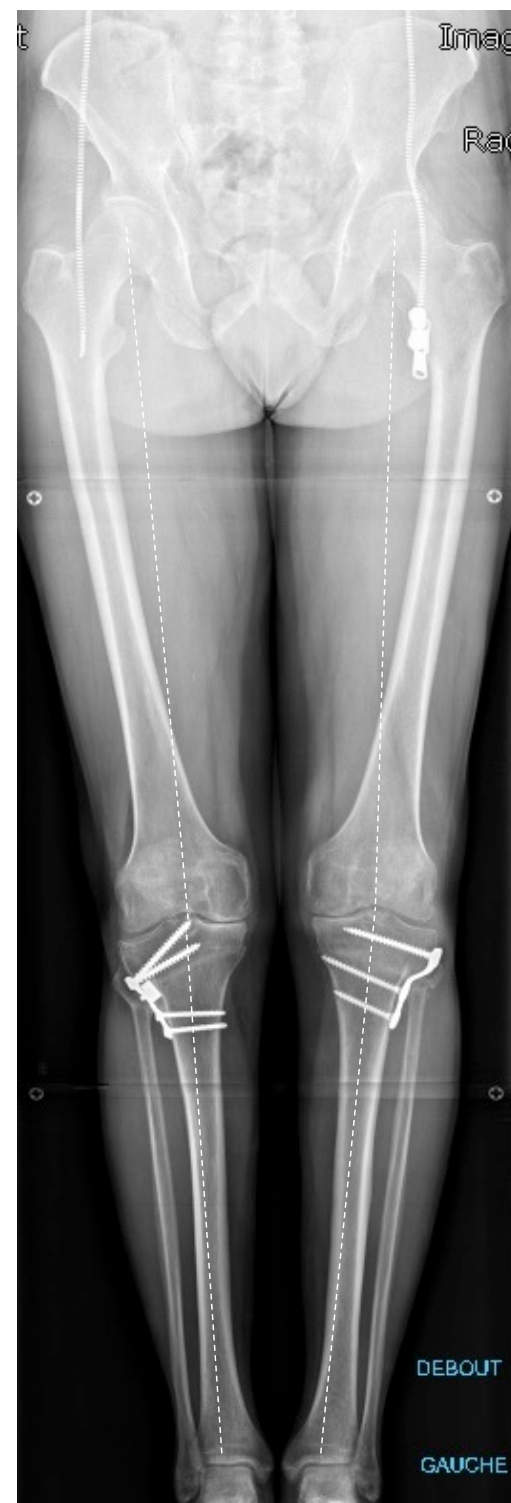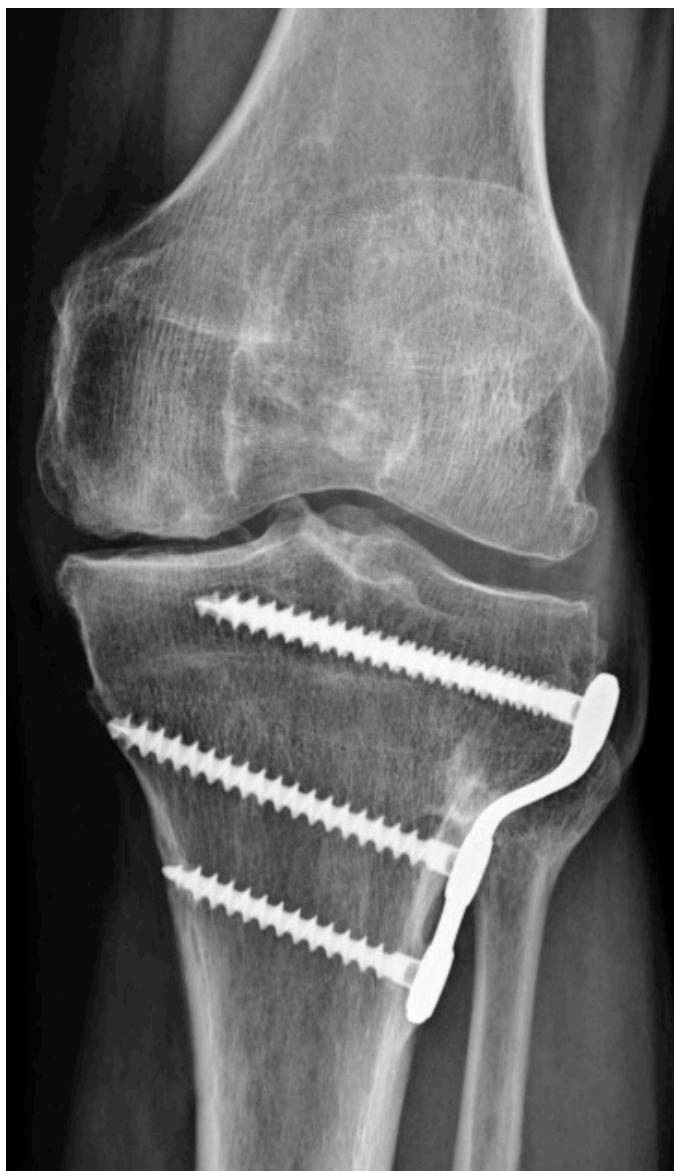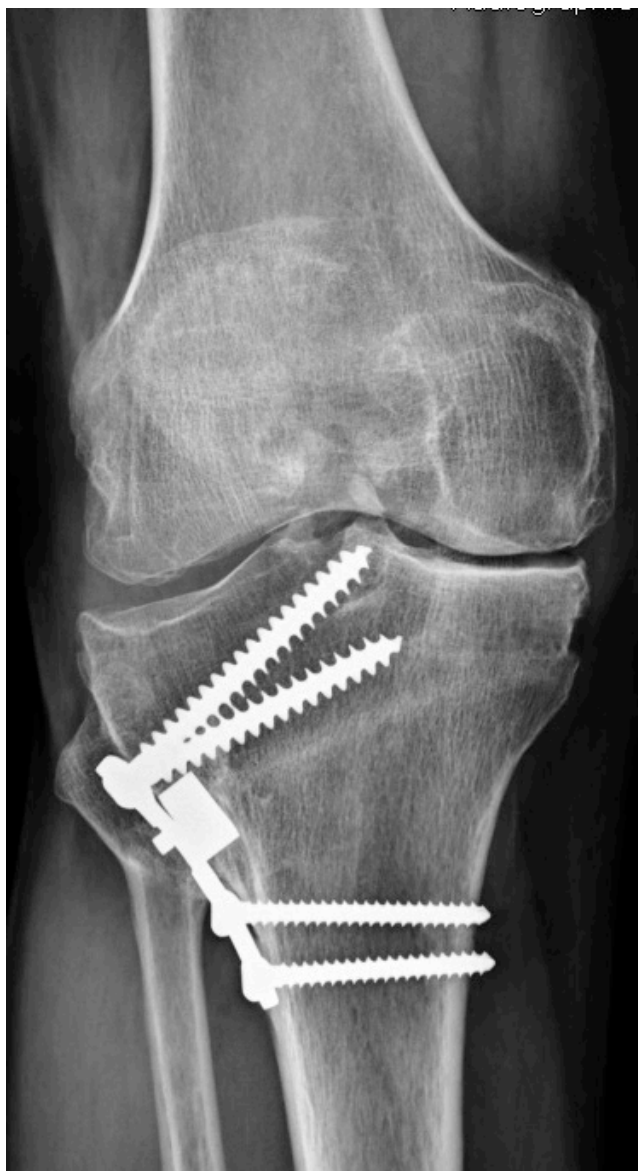'Ideal patient'

1

Male - active - born in 1954



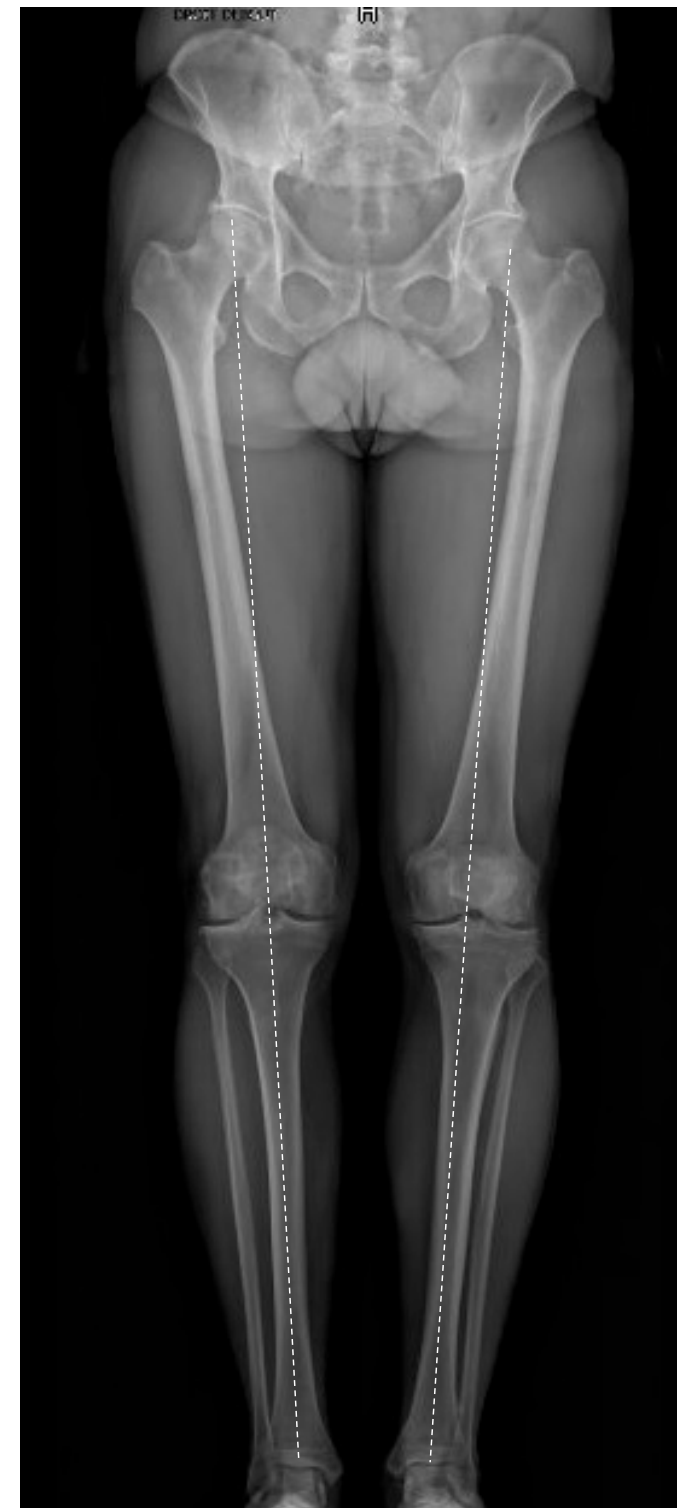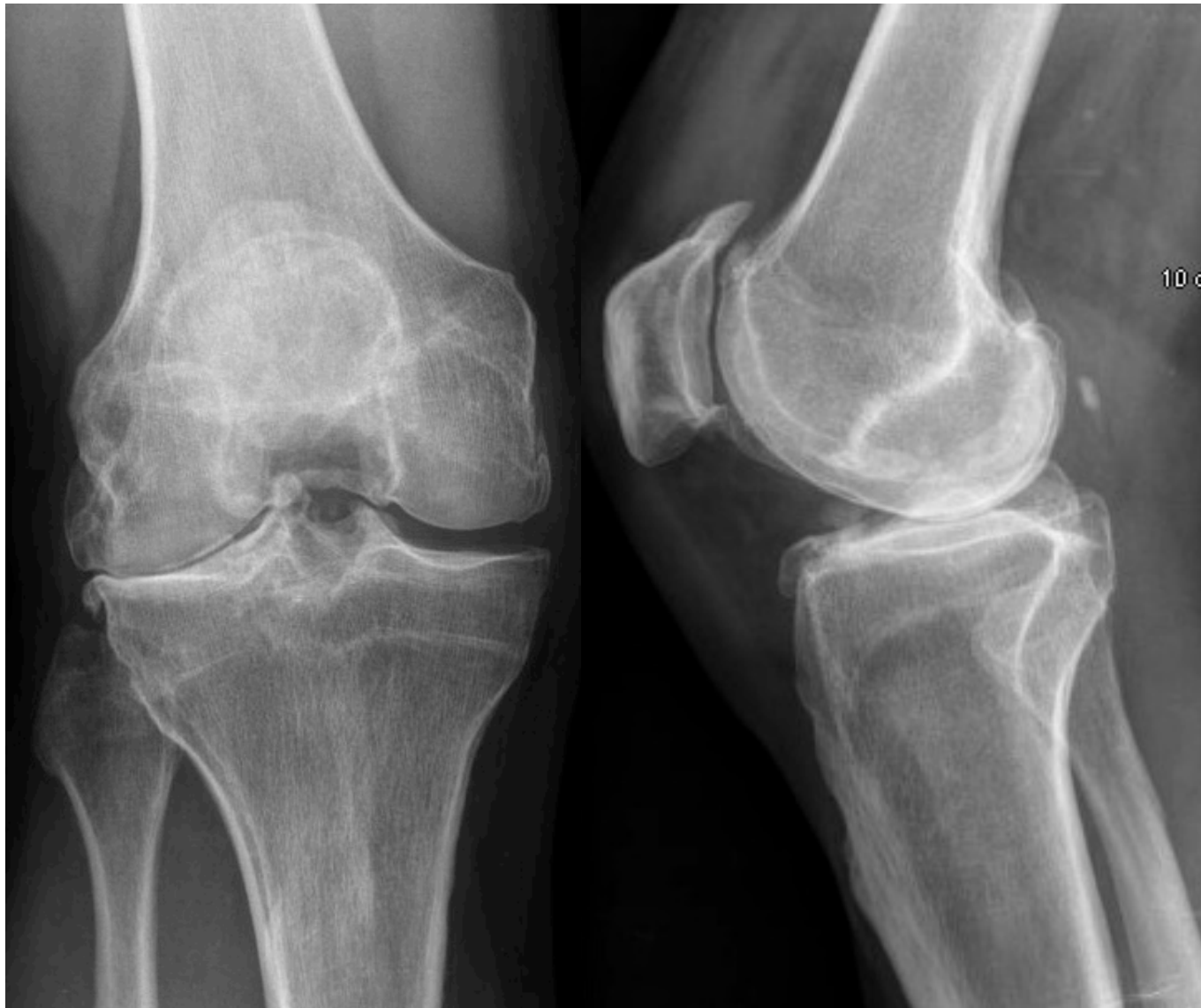
		Osteotomy	UKA
1- Alignment	• Well-aligned		X
	• Constitutional	✓	
	• Reductibility		X
2- Patello-Femoral Joint			✓
3- Contro-lateral compartment		✓	✓
4- ACL			✓
5- Bone Quality		✓	✓
6- Age < 65		✓	
7- Spine correct		✓	

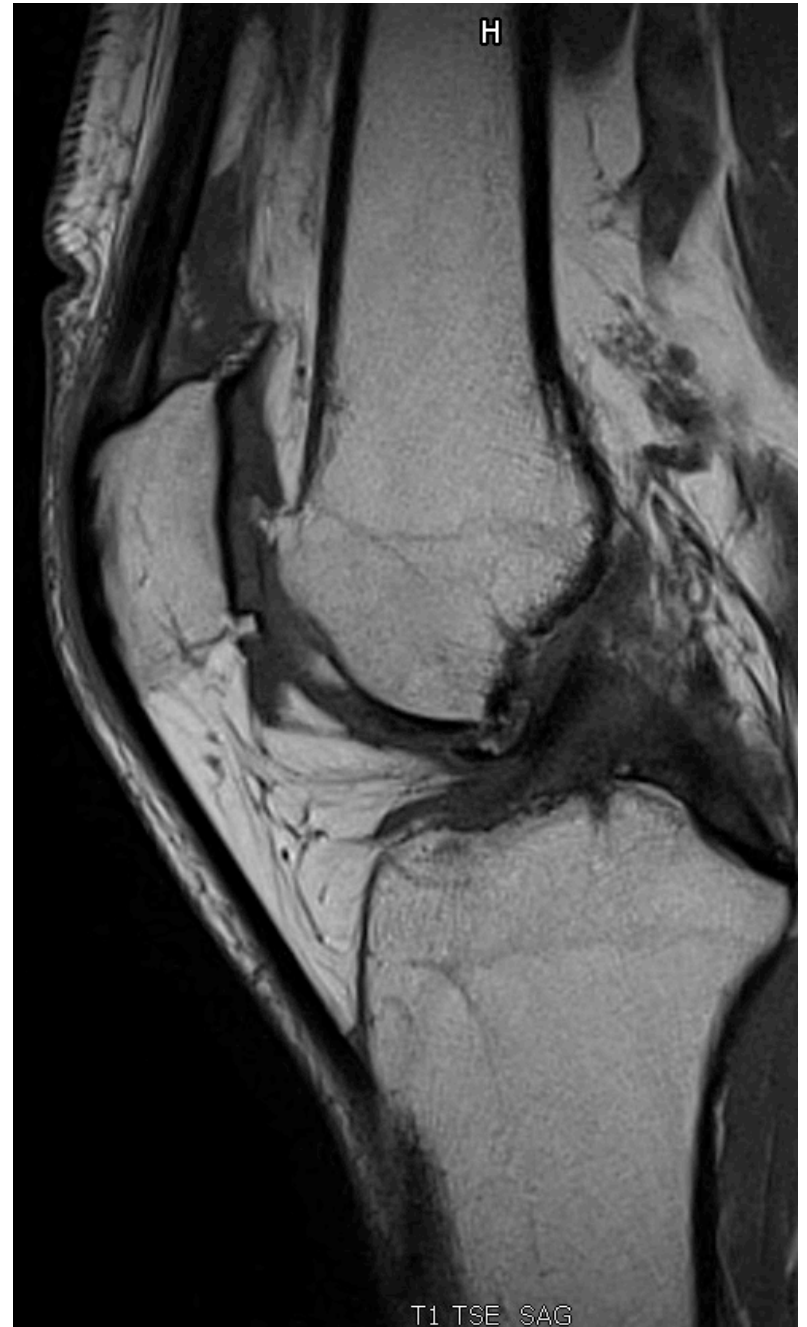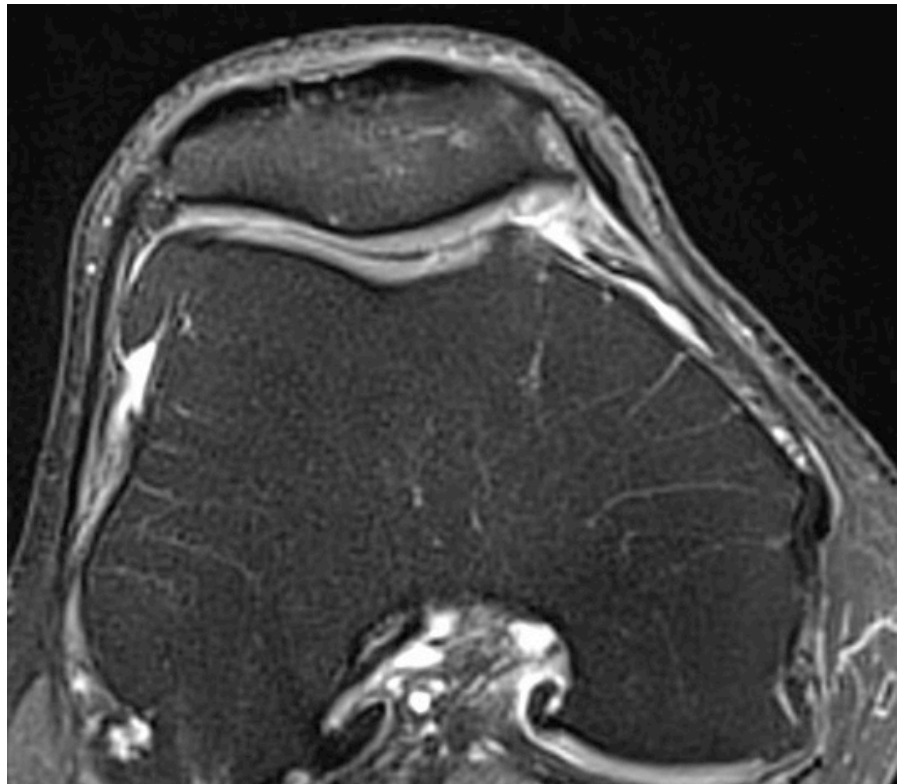
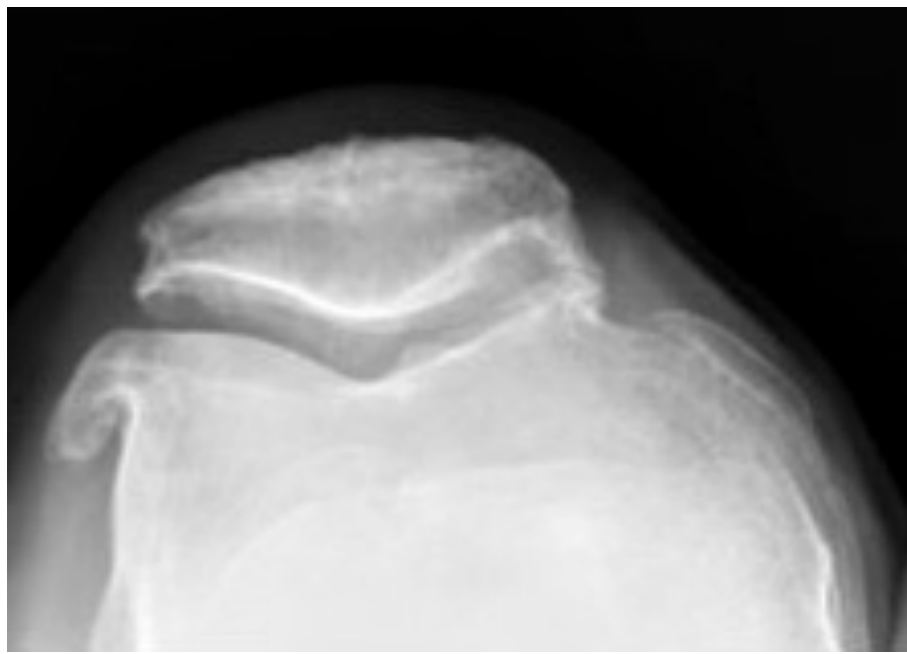


'severe lateral'

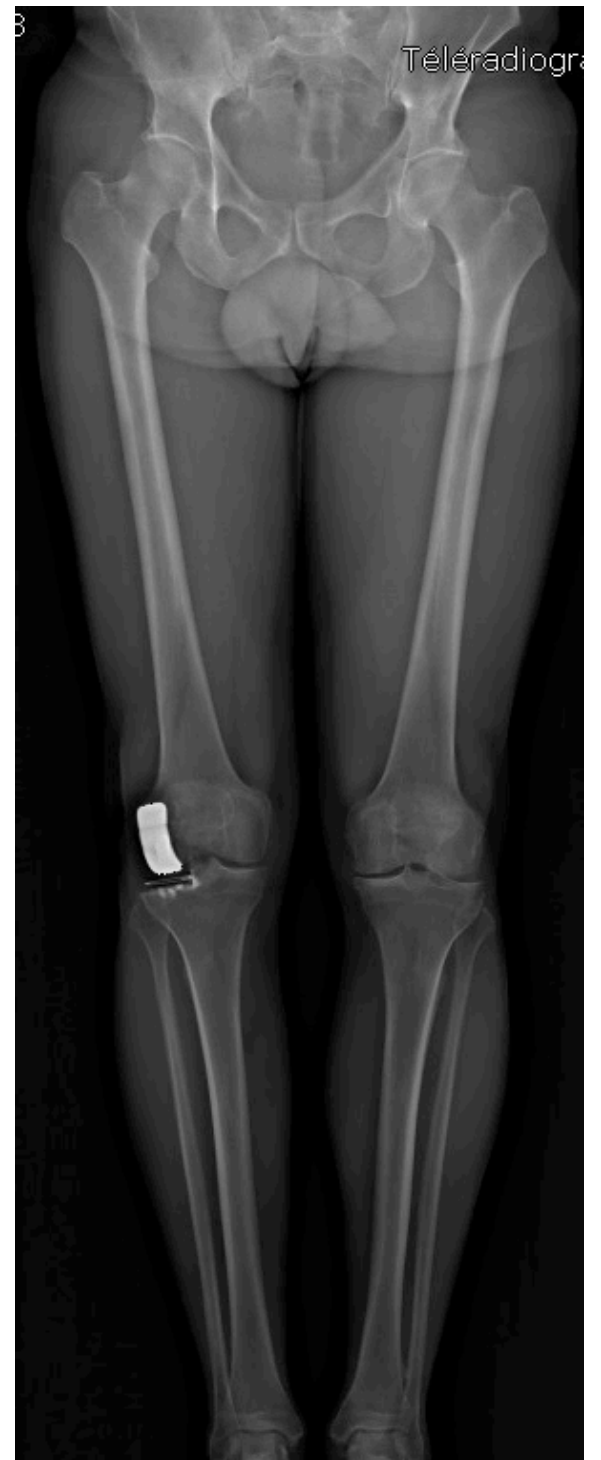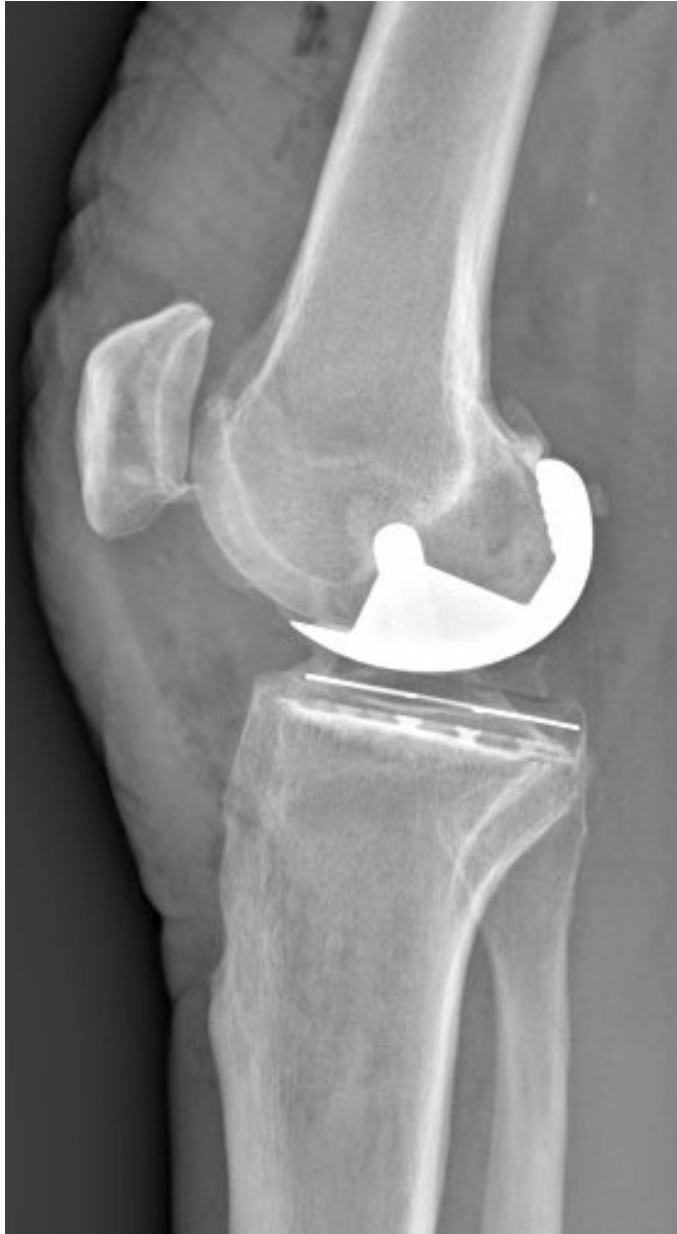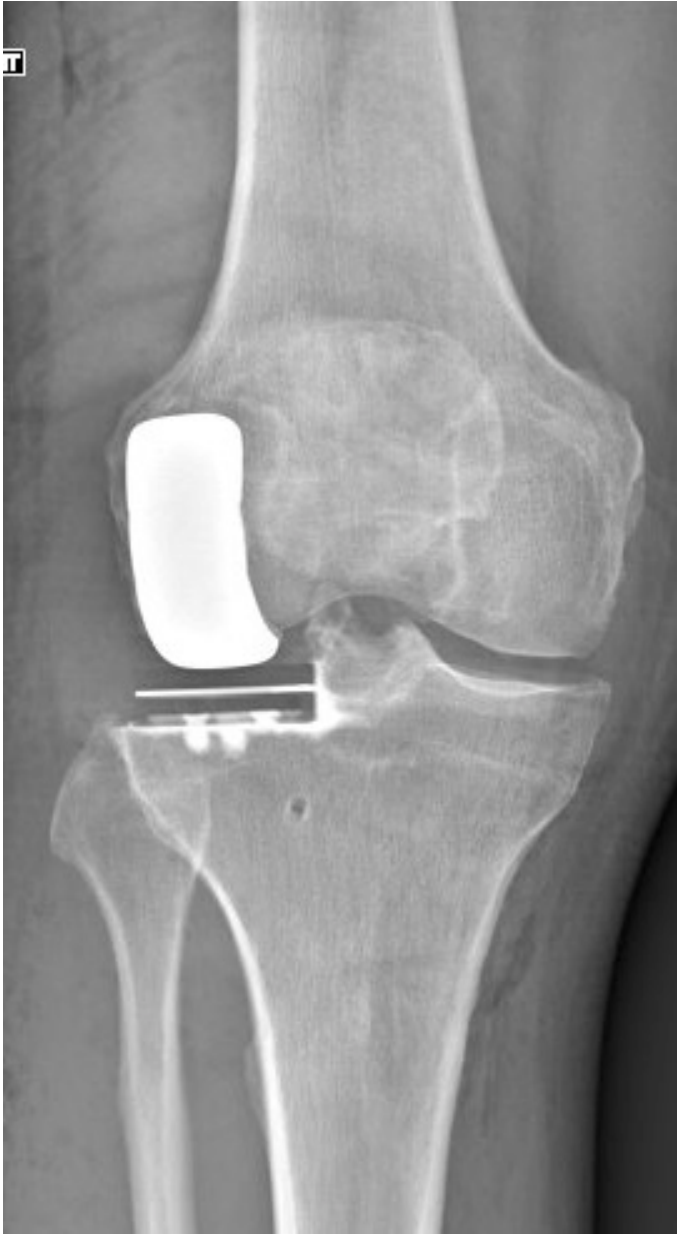2

Male - Mountain climbing +++
Disabled in daily life- born in 1943 (72)





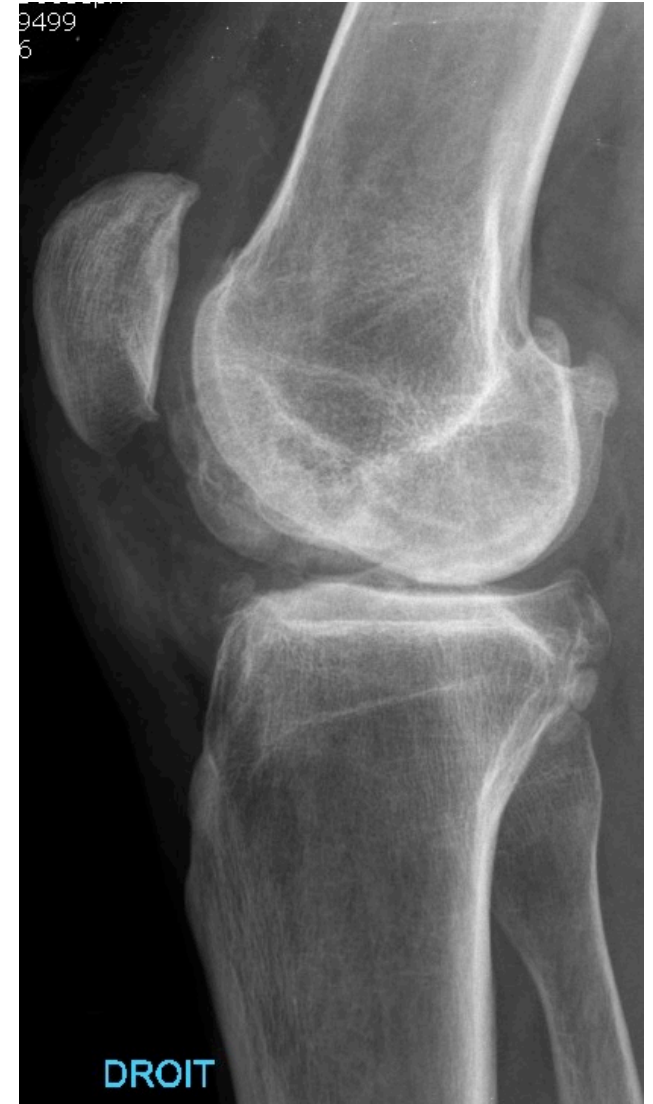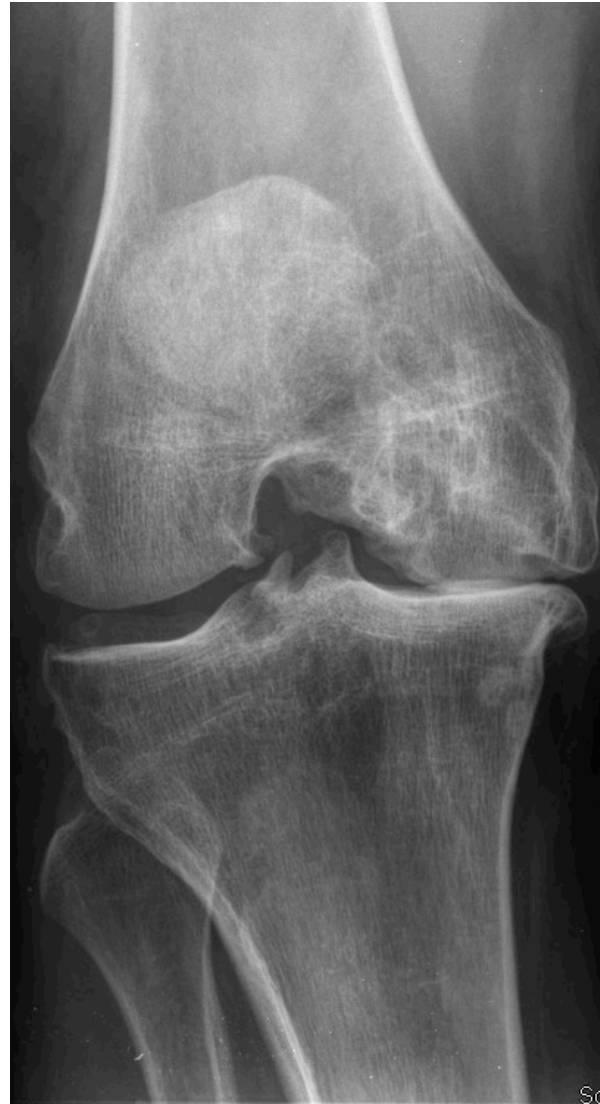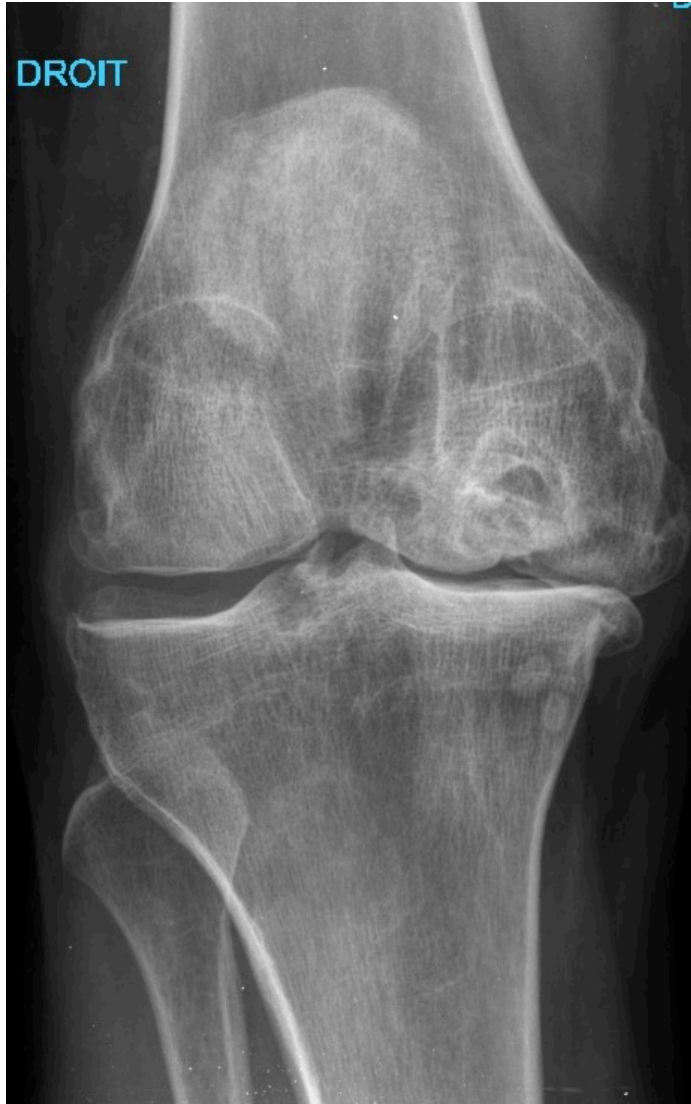		Osteotomy	UKA
1- Alignment	• Well-aligned	X	✓
	• Constitutional		
	• Reductibility		✓
2- Patello-Femoral Joint			✓
3- Contro-lateral compartment		✓	✓
4- ACL			✓
5- Bone Quality		✓	✓
6- Age < 65		X	
7- Spine correct		✓	

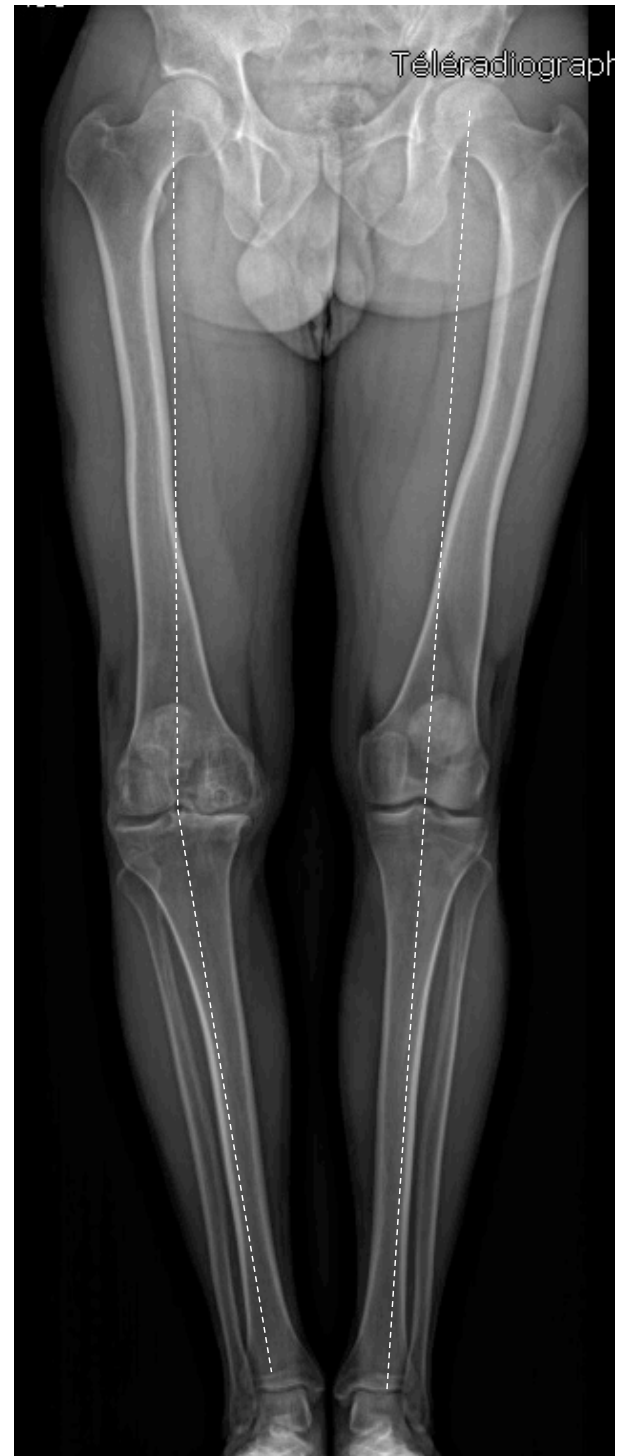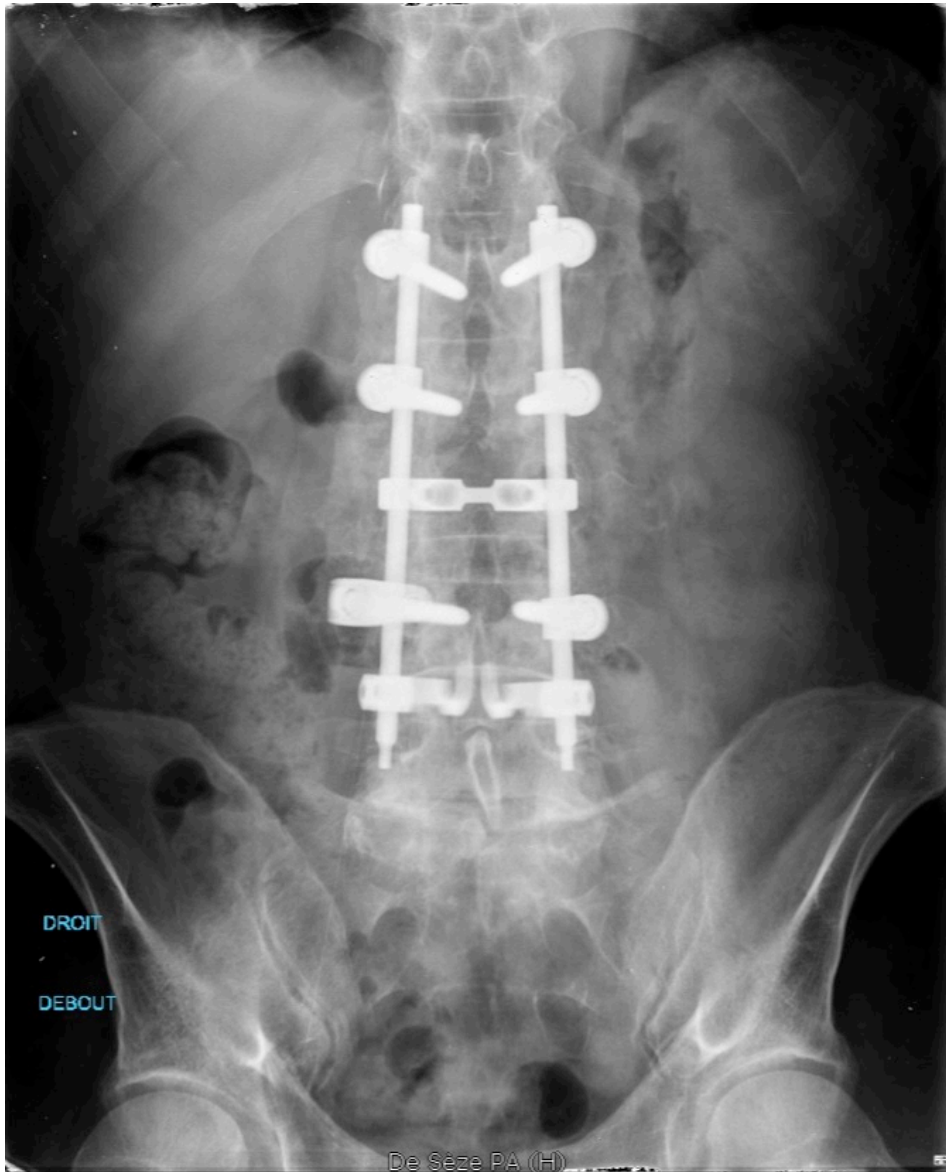


'post traumatic medial'

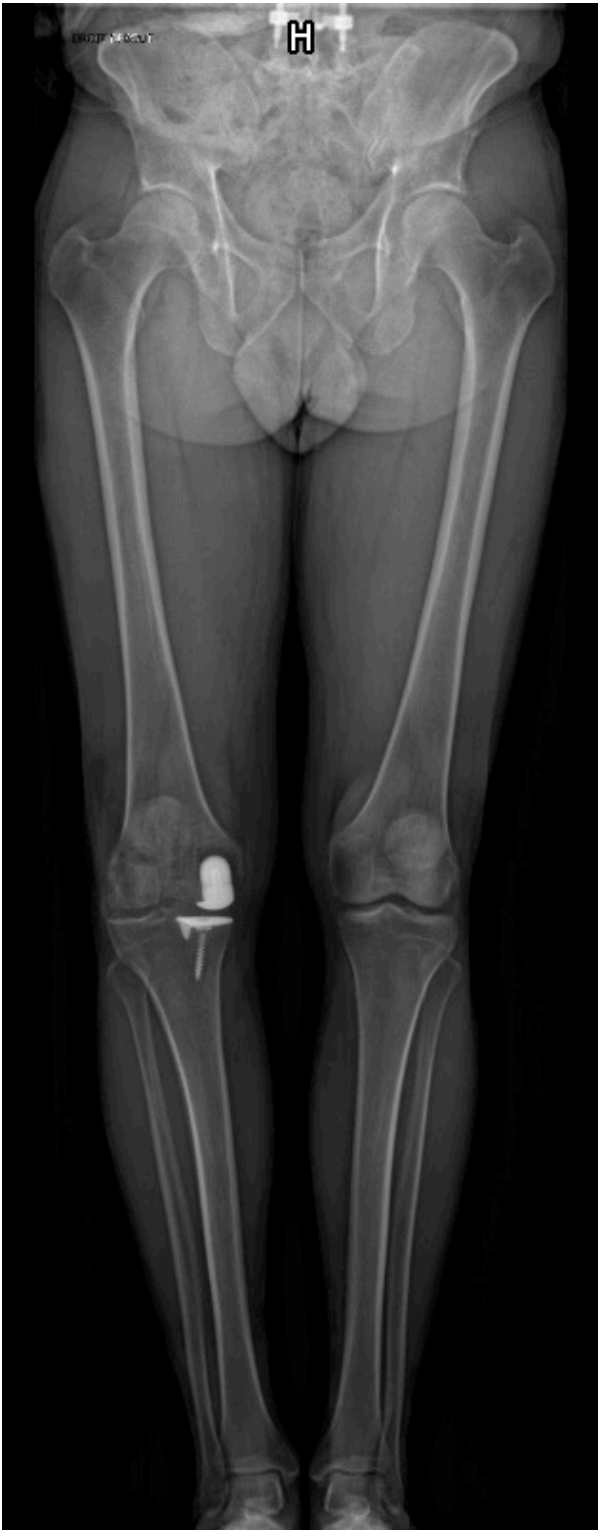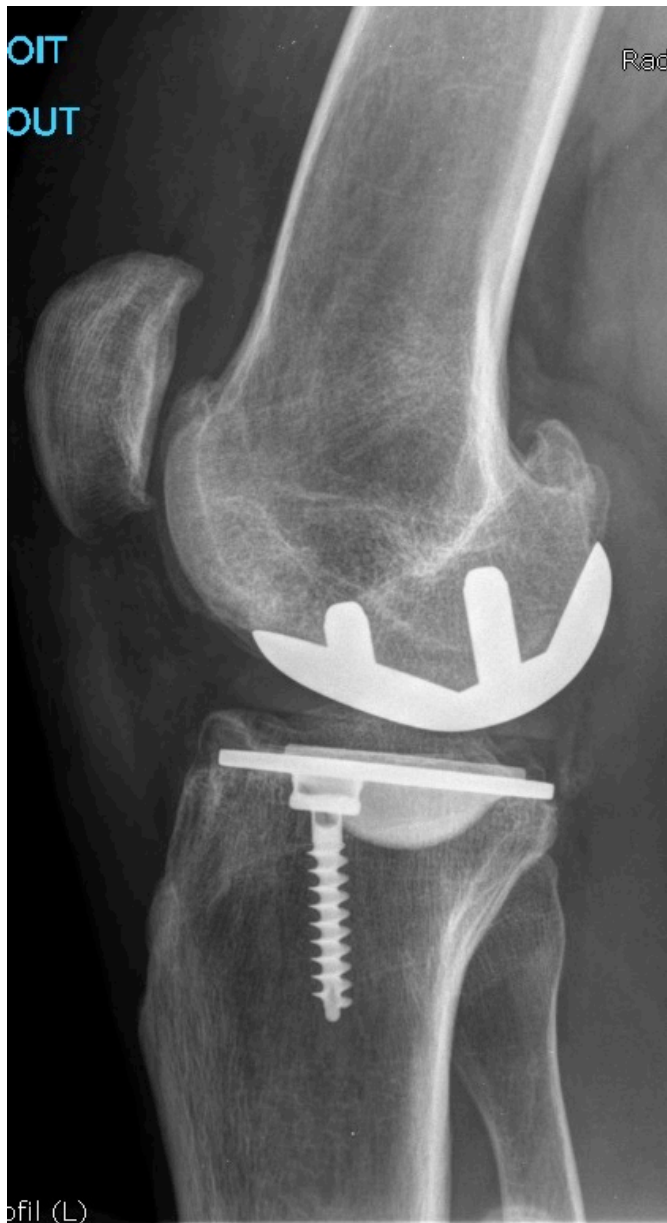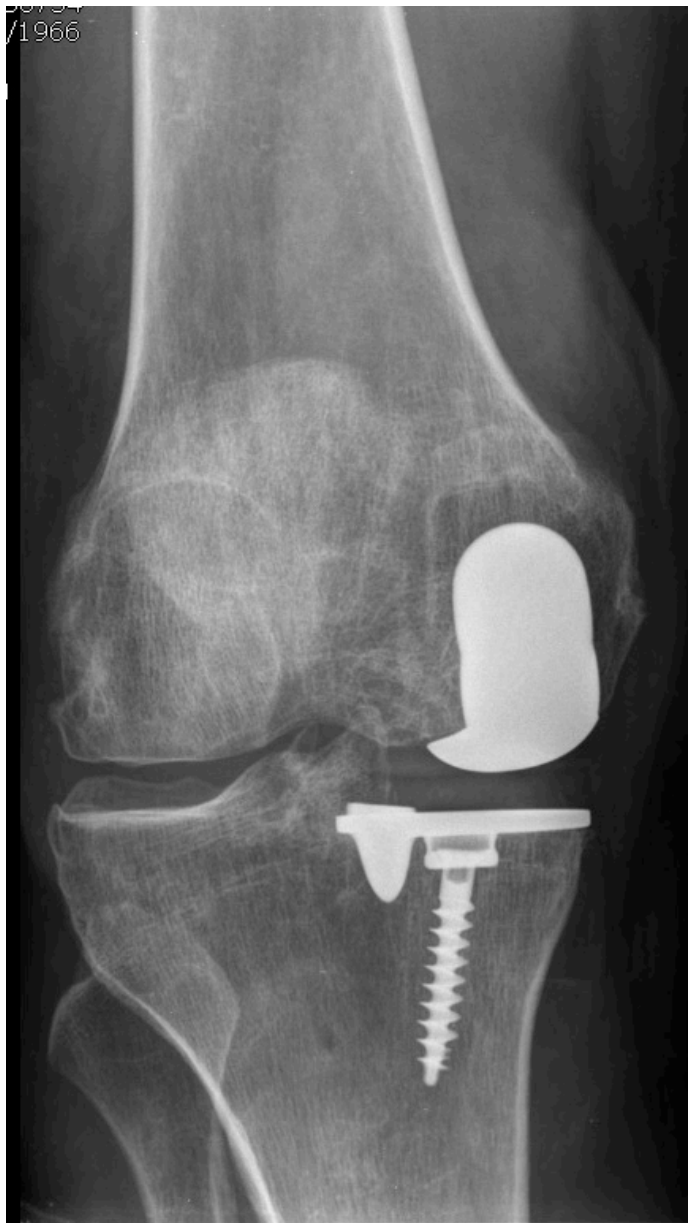3

Male - active - gun shot 15 y ago -
cycling athlete retired - born in 1966 (49)





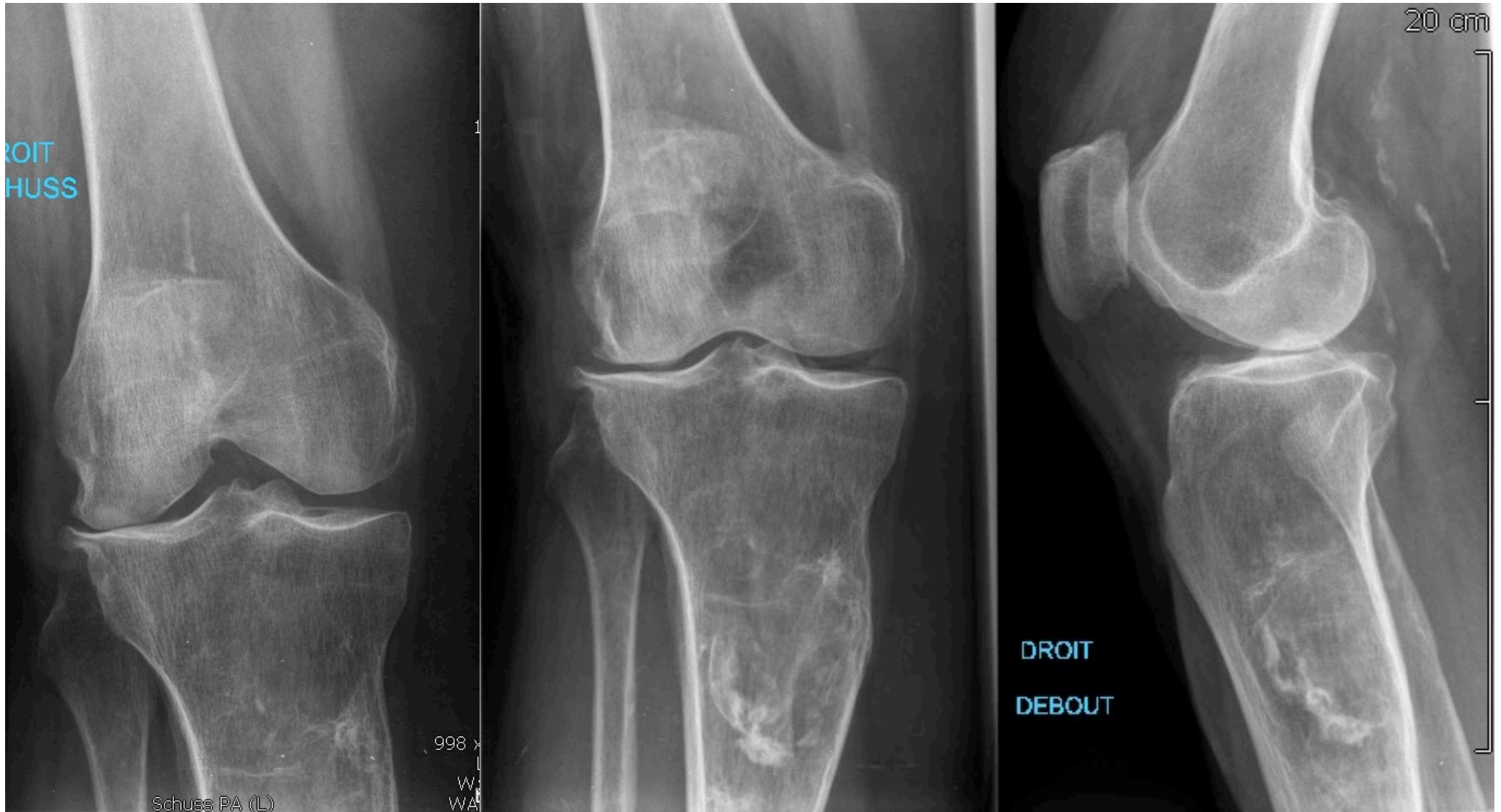
		Osteotomy	UKA
1- Alignment	• Well-aligned	X	✓
	• Constitutional		
	• Reductibility		✓
2- Patello-Femoral Joint			✓
3- Contro-lateral compartment		✓	✓
4- ACL			✓
5- Bone Quality		✓	✓
6- Age < 65		✓	
7- Spine correct		X	

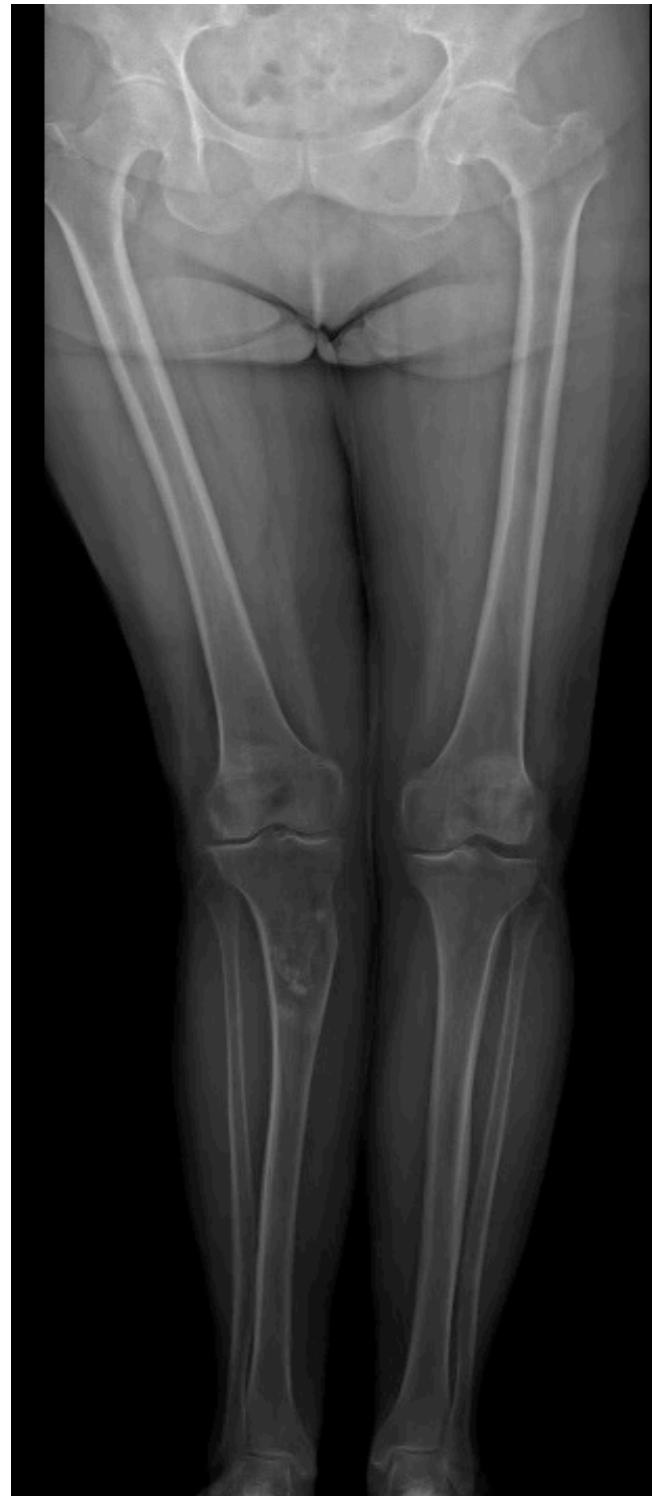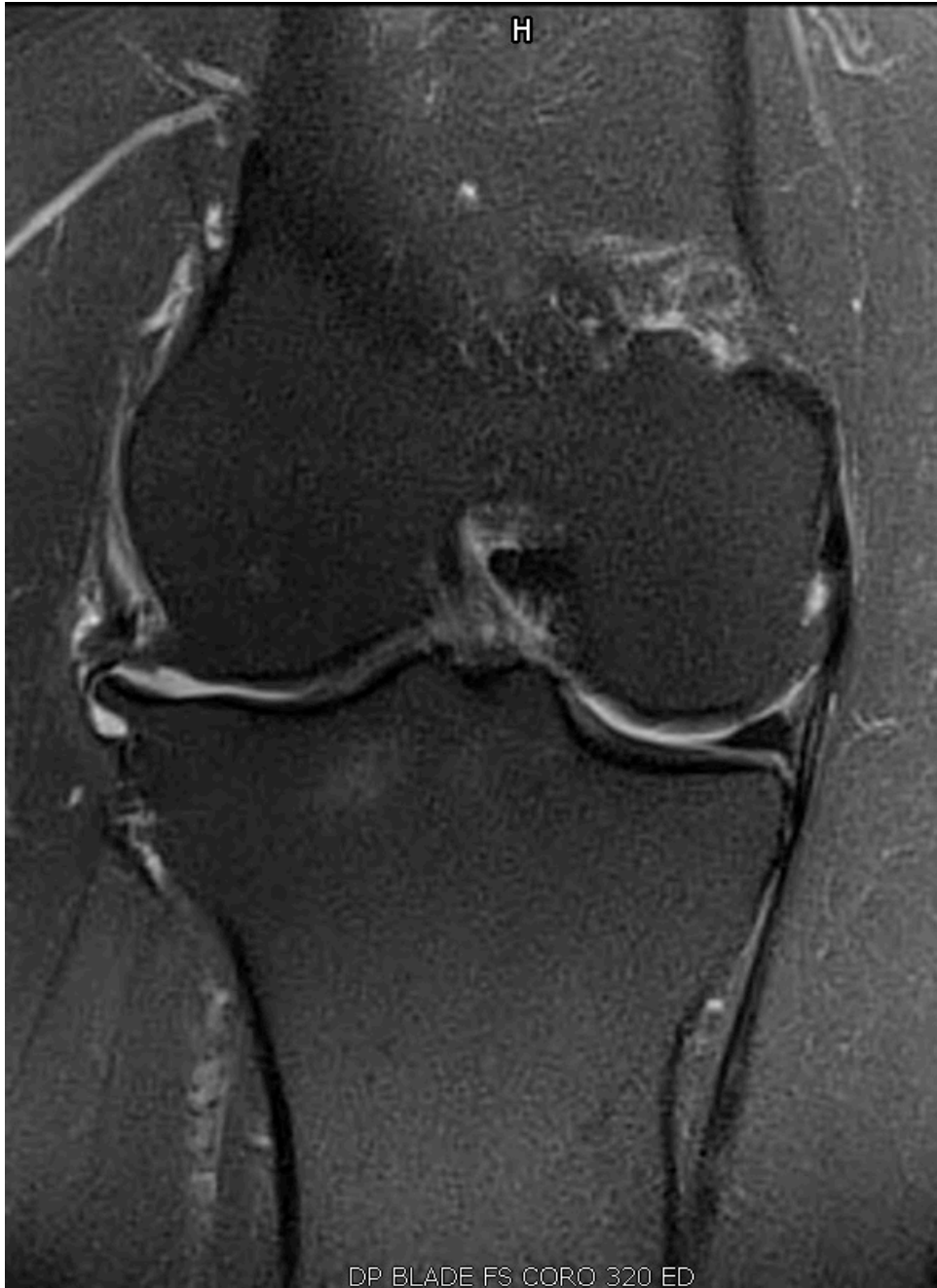


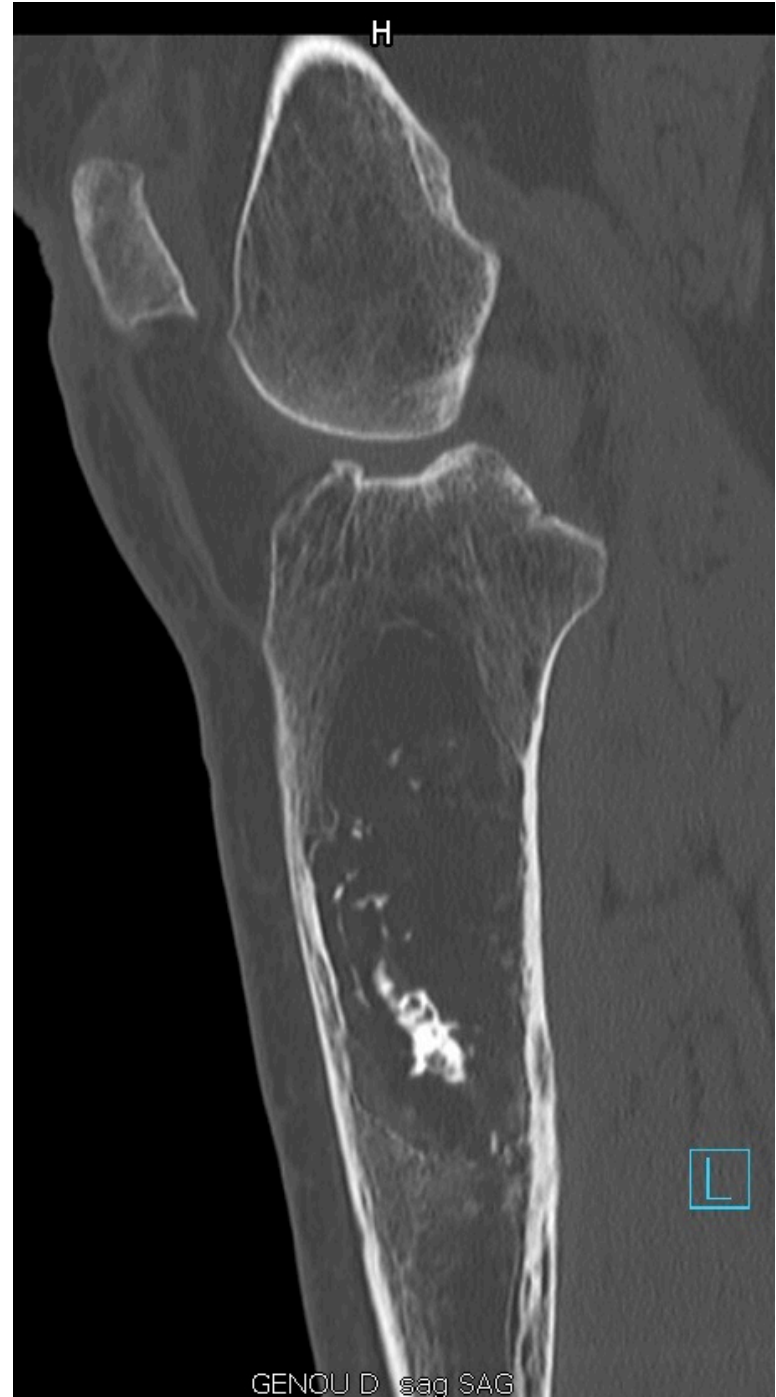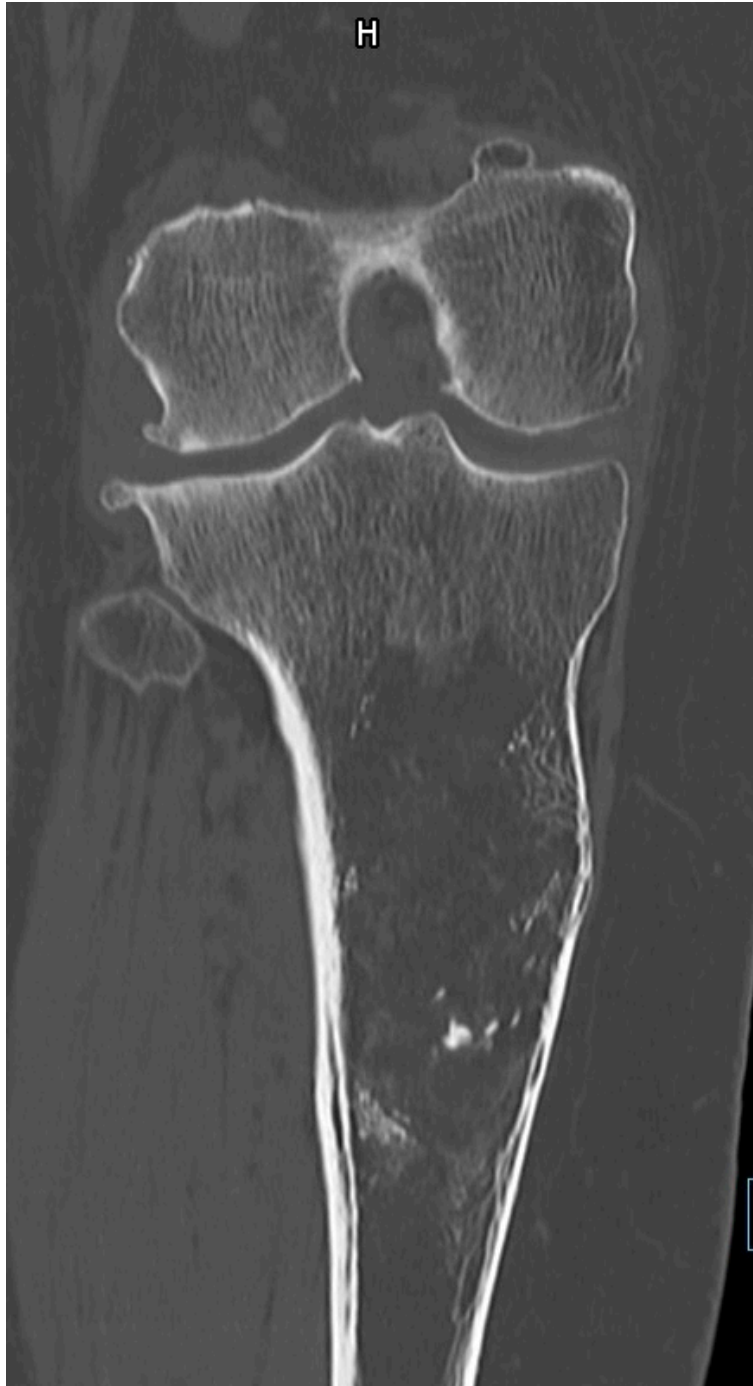ofil (L)

4

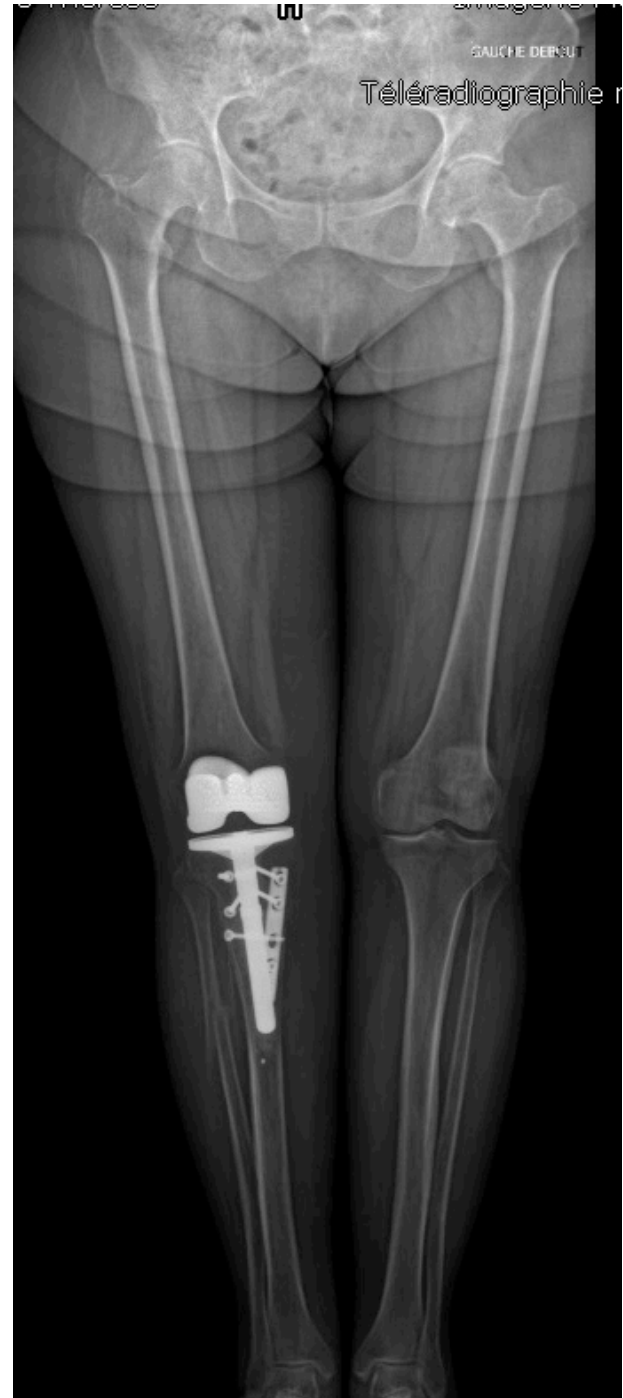
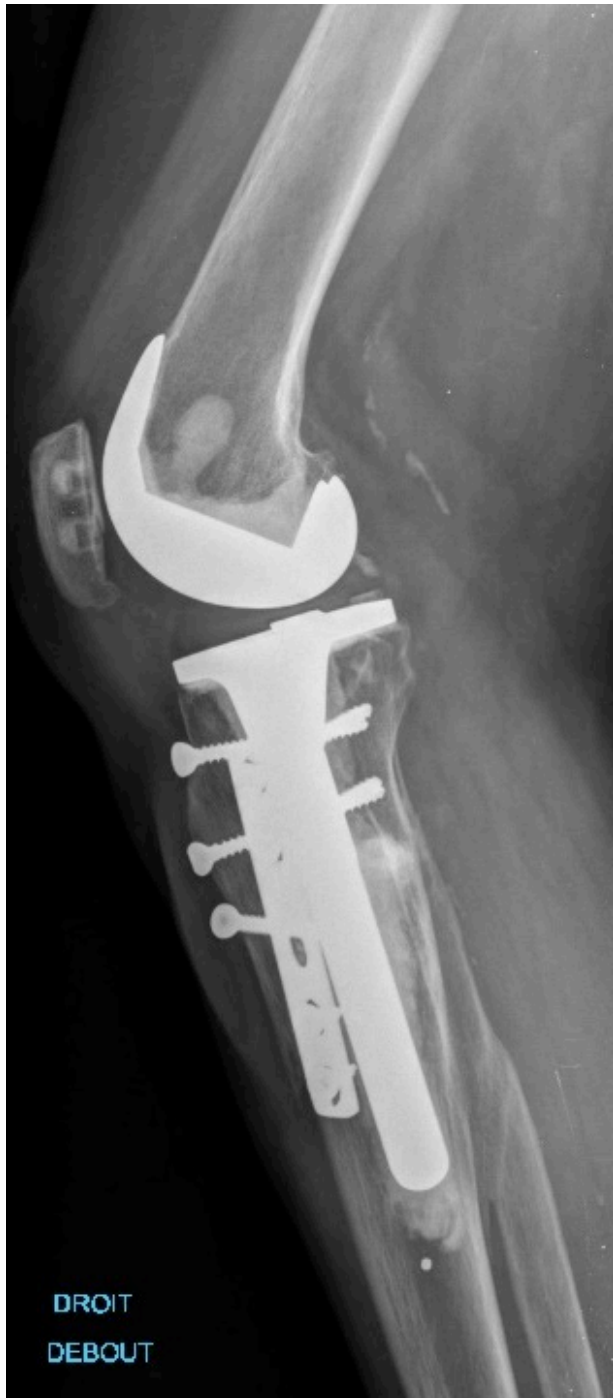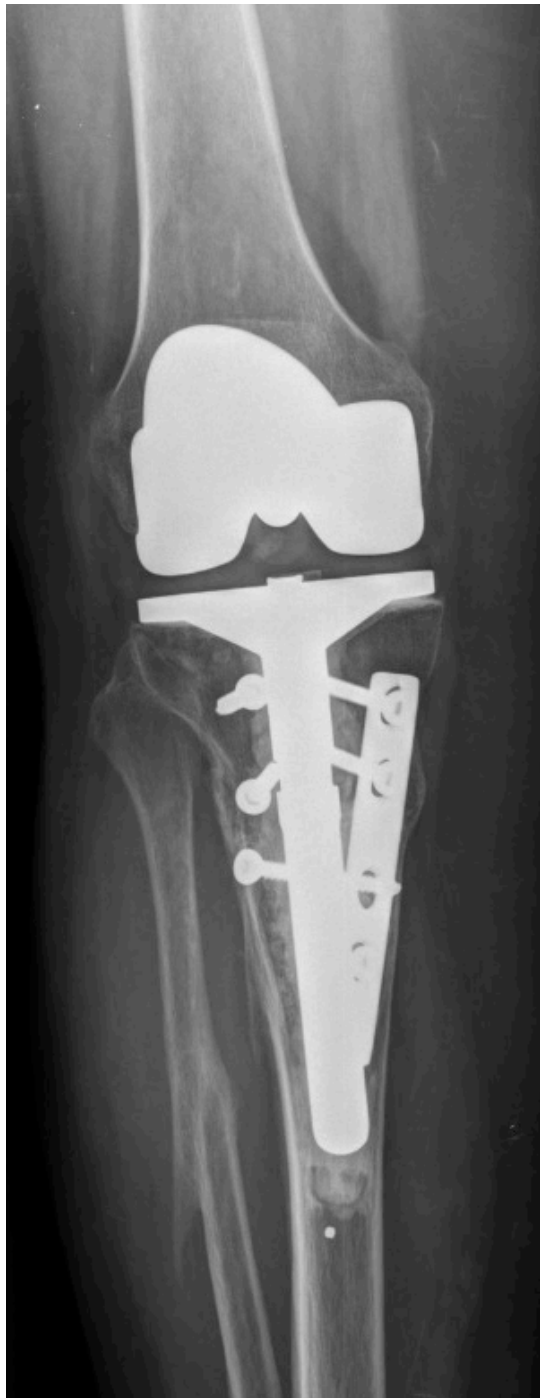Female - giant cell tumor 30 years ago- Disabled in daily life - born in 1940





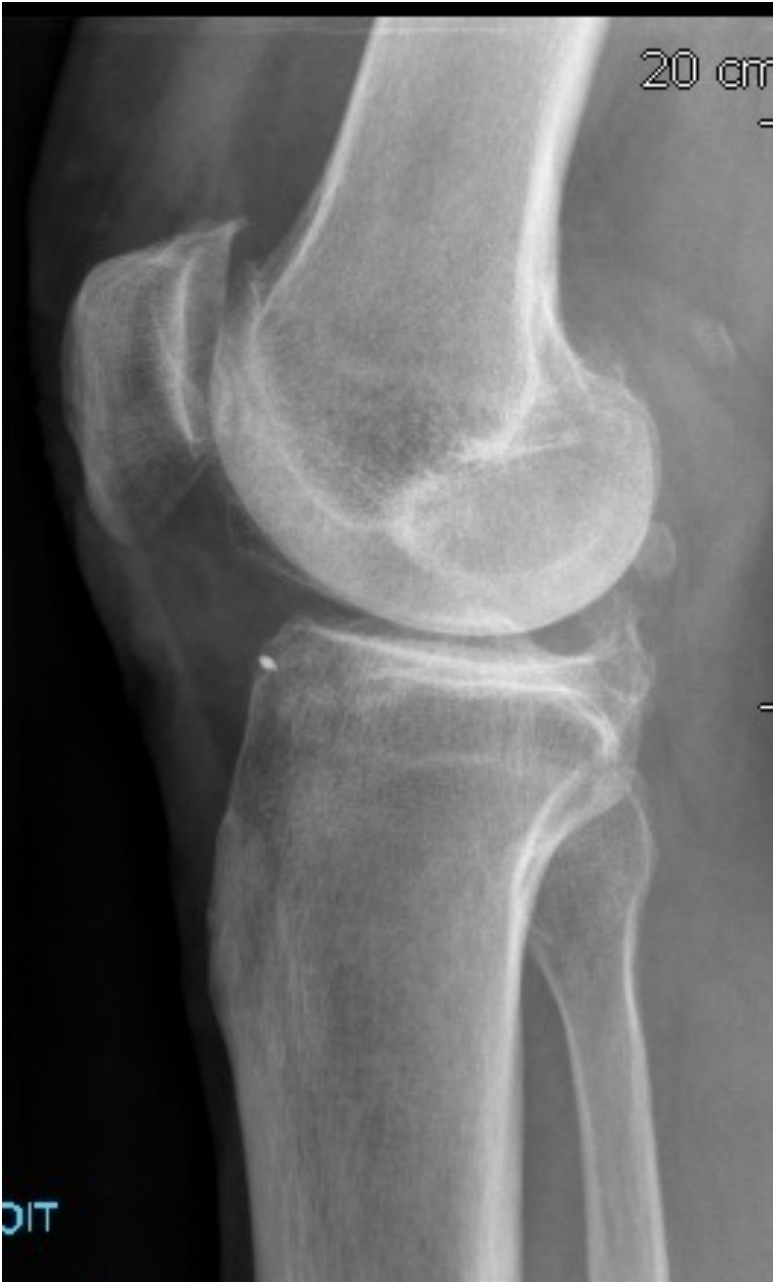
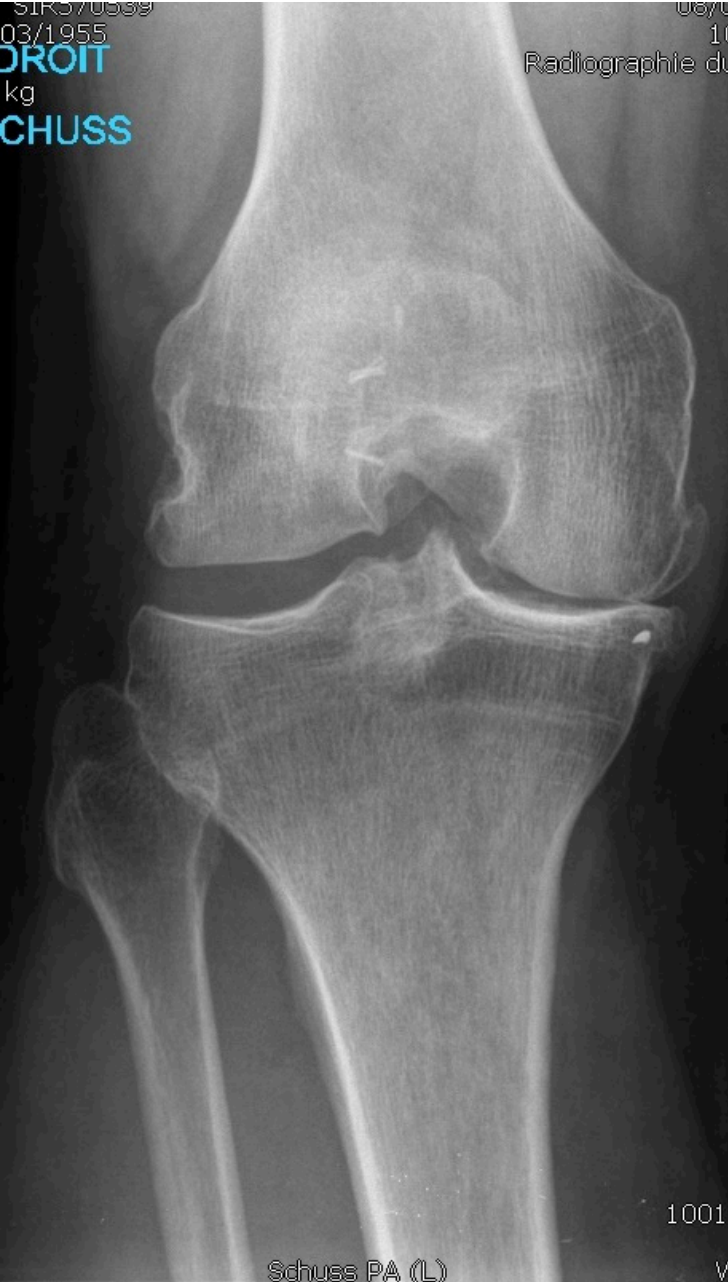
		Osteotomy	UKA
1- Alignment	• Well-aligned		✓
	• Constitutional	✓	
	• Reductibility		✓
2- Patello-Femoral Joint			✓
3- Contro-lateral compartment		✓	✓
4- ACL			✓
5- Bone Quality		✗	✗
6- Age < 65		✗	
7- Spine correct		✓	

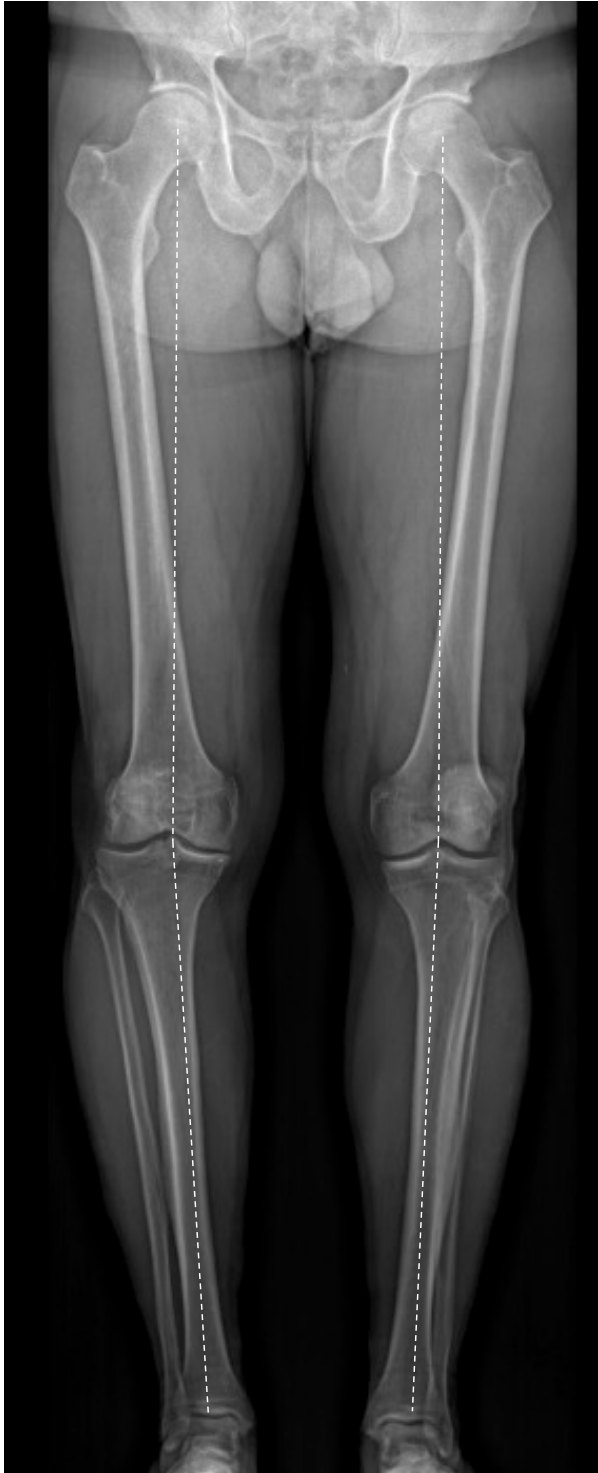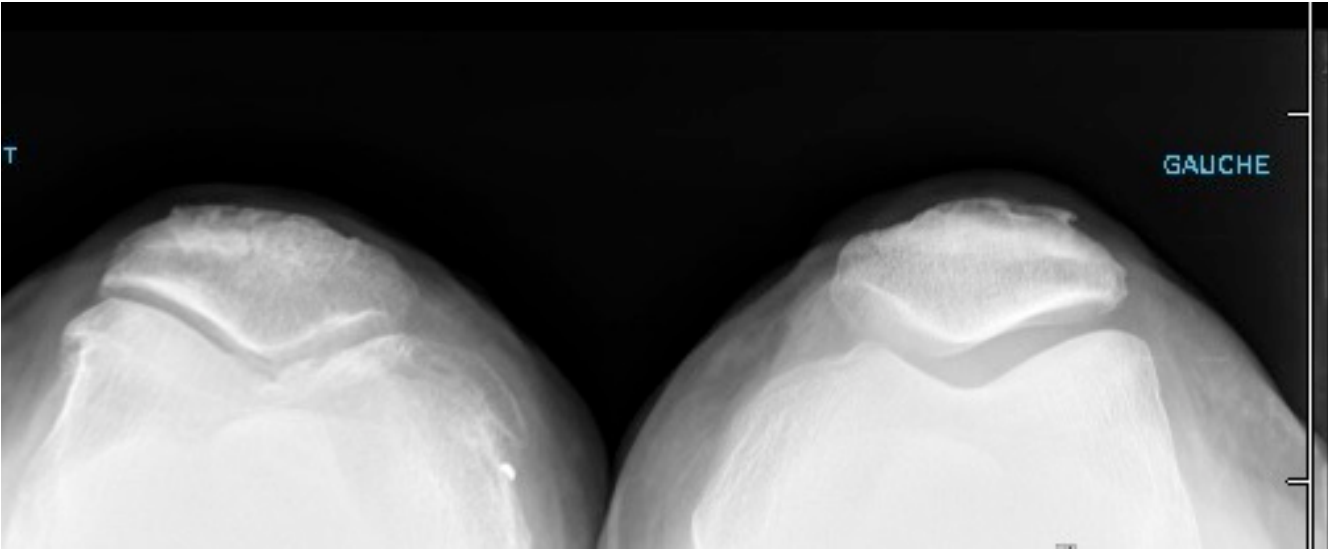


5

Male - active - medial meniscectomy-
cycling athlete retired - born in 1955

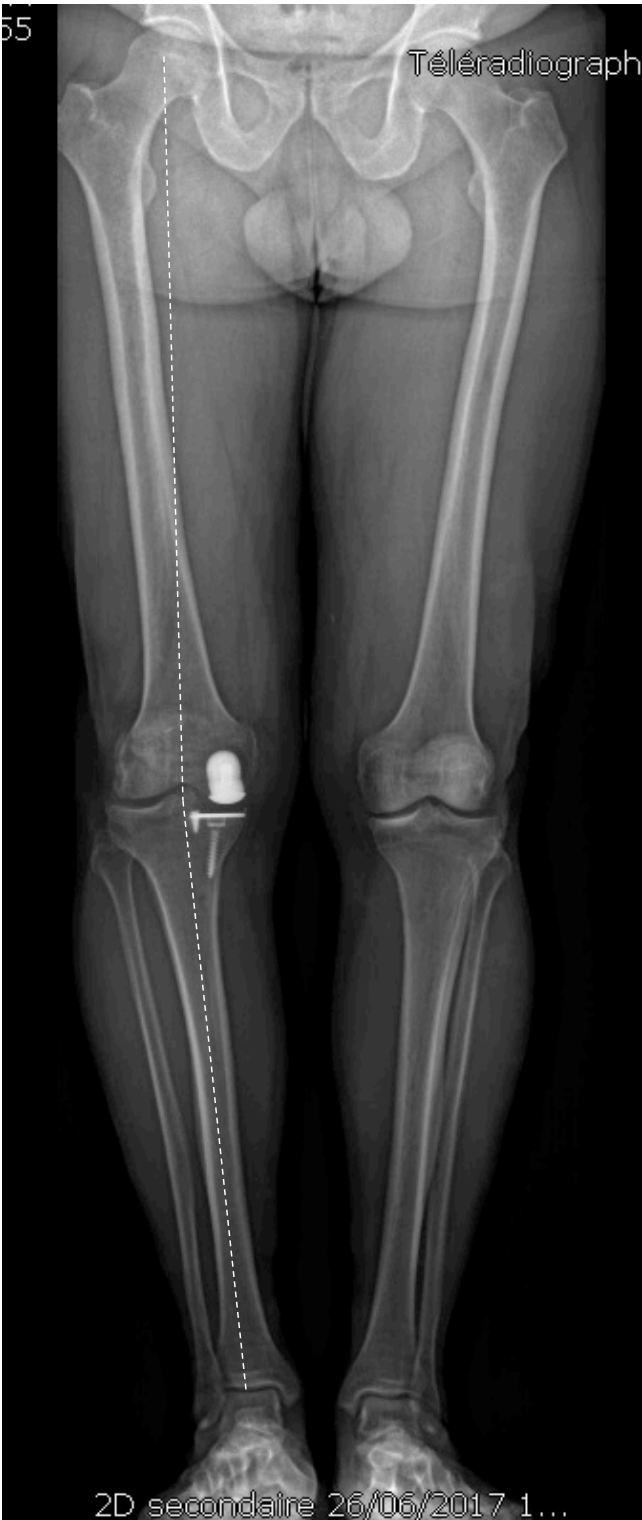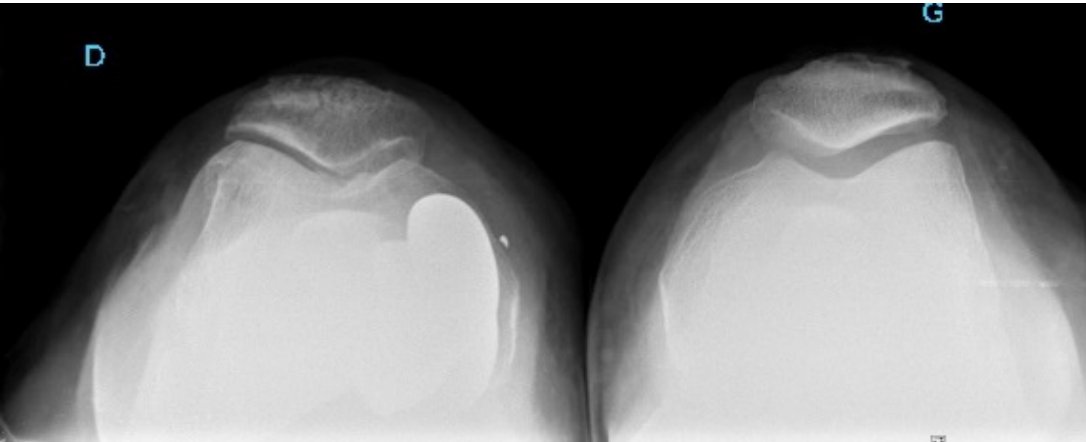
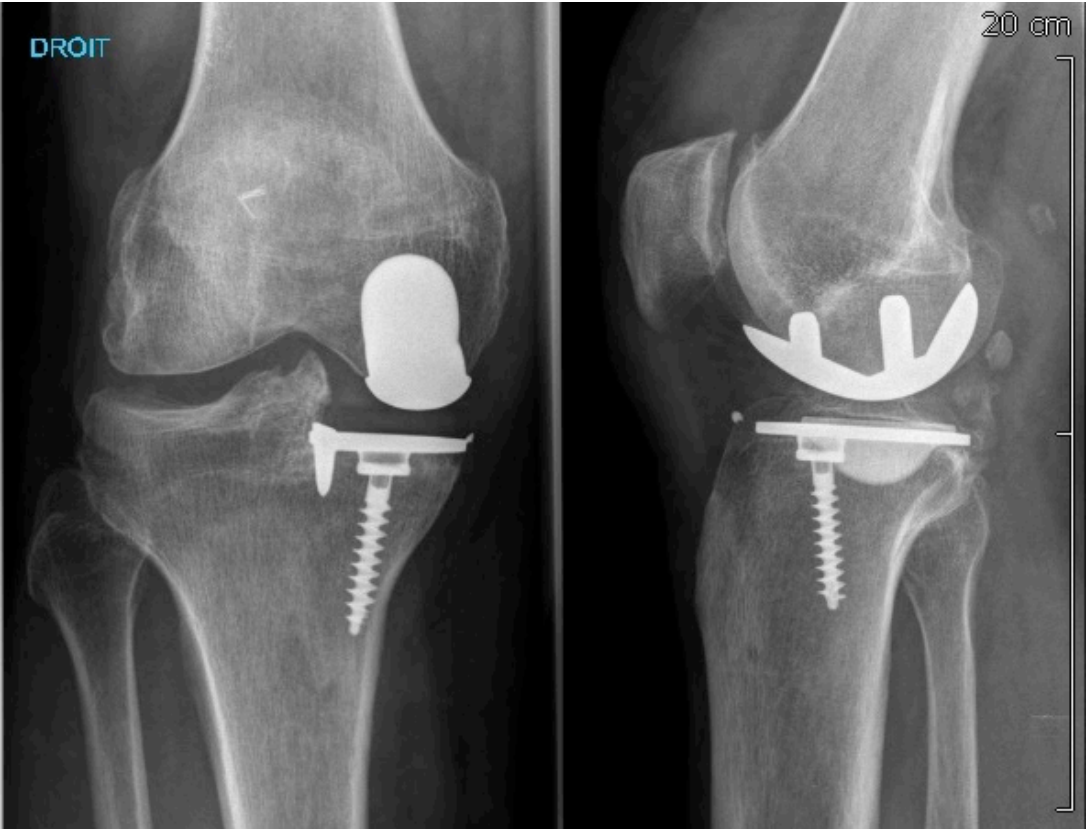


Male - active - medial meniscectomy-
cycling athlete retired - born in 1955



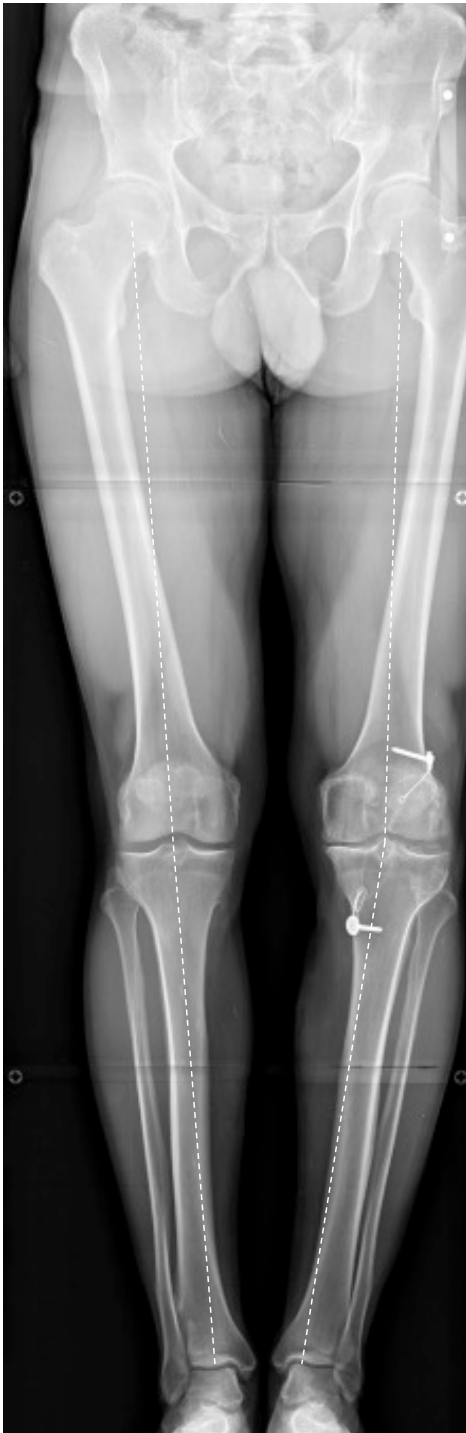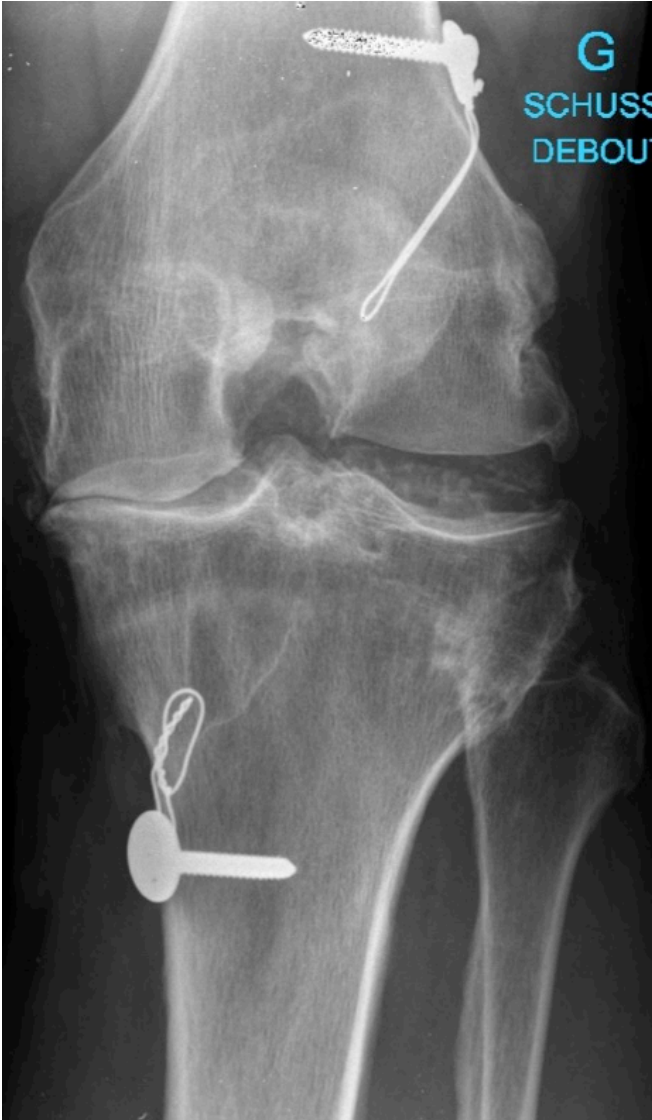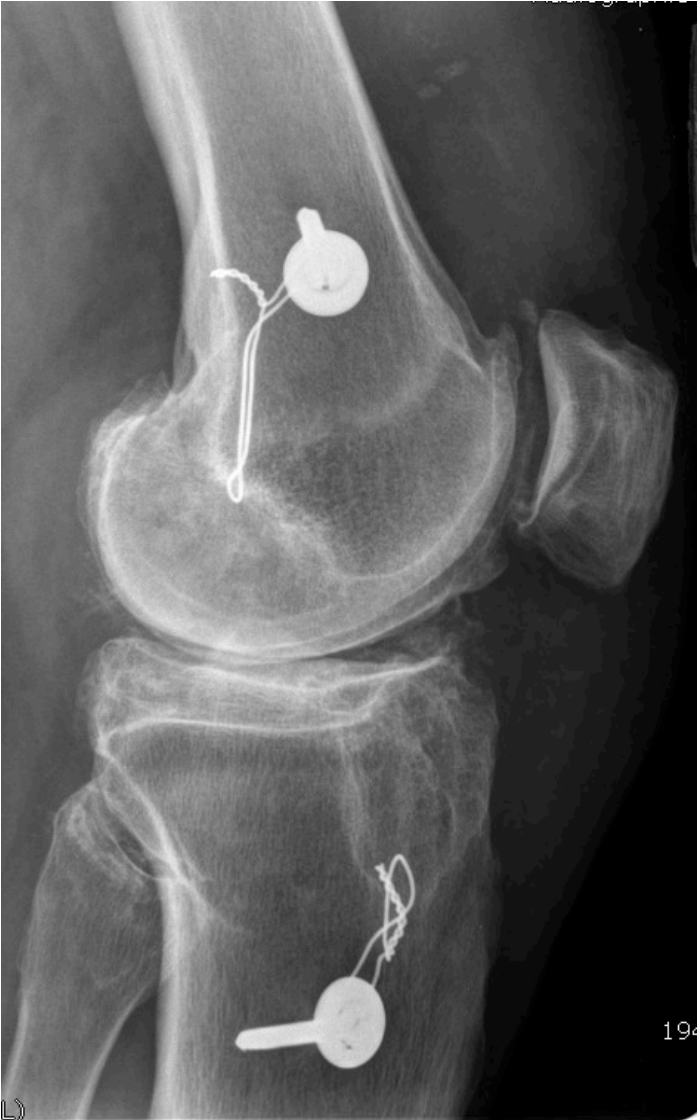		Osteotomy	UKA
1- Alignment	• Well-aligned	X	✓
	• Constitutional		
	• Reductibility		✓
2- Patello-Femoral Joint			✓
3- Contro-lateral compartment		✓	✓
4- ACL			✓
5- Bone Quality		✓	✓
6- Age < 65		✓	
7- Spine correct		✓	

Male - active - medial meniscectomy - cycling athlete retired - born in 1955



6

Male - active - ACL graft - Anterior laxity
born in 1951- operated in 2015 (64y)



		Osteotomy	UKA
1- Alignment	• Well-aligned	X	✓
	• Constitutional		
	• Reductibility		✓
2- Patello-Femoral Joint			✓
3- Contro-lateral compartment		✓	✓
4- ACL			X
5- Bone Quality		✓	✓
6- Age < 65		✓	
7- Spine correct		✓	

